

From the Division of Radiology
Department of Clinical Science, Intervention and Technology

Karolinska Institutet, Stockholm, Sweden

A New Computed Tomography Method for Evaluation of Orthopedic Implants

Applied to the Acetabular Cup

Lotta Olivecrona



**Karolinska
Institutet**

Stockholm 2010

All previously published papers were reproduced with permission from the publisher.

Published by Karolinska Institutet. Printed by Universitetservice UA-AB

© Lotta Olivecrona, 2010
ISBN 978-91-7409-751-1

To
Rose and Jan

ABSTRACT

Background: Two major long term complications after total hip arthroplasty (THA) are aseptic loosening and wear of the implant. In the follow up of THA operations radiological evaluation has an important role to play. In the clinical situation a detection level of approximately 1 mm is commonly accepted as being desirable. However, conventional planar radiographs used in clinical routine cannot reach this level. There are other planar radiographic methods, with a higher degree of accuracy, but they are either invasive or too complicated for routine use. Consequently a new non-invasive method for more accurate routine evaluation of orthopedic implants, is needed.

Aims: To develop and test a new computed tomography (CT) method for evaluation of migration and wear of orthopedic implants. With the pelvis, acetabular cup and femoral component head as a model system, volume registration of CT data was used for migration detection, together with landmarking of the prosthetic components to get a numerical correlate of both migration and wear. Also an image post processing tool for standard orientation was validated.

Method

Study I: Two CT scans, ten minutes apart, were obtained from each of ten patients after total hip arthroplasty. A locally developed semiautomated program for volume registration (merging) was used to fuse the pelvis of the two examinations. The acetabular cup was then evaluated visually and numerically to test the method's accuracy for migration detection.

Study II: Twenty-six CT scans of a pelvic model were obtained while altering the position of an acetabular cup. Using the same program for volume registration as in Study I, the pelvis from different scans was fused, and the differences in cup position were evaluated visually and numerically by two examiners. The results were compared to direct measurements on the model.

Study III: Twenty-four CT volumes from the model study and the 10 pairs of post operative CT volumes from Study I were rotated to a defined pelvic standard orientation and the rotation recorded.

Study IV: Eight uncemented cups with femoral components were scanned twice with CT ex vivo. The linear penetration depth of the femoral component into the cup and the thickness of the remaining polyethylene were measured in the CT volumes. Each volume was assessed twice by two examiners. The CT measurement was compared to direct measurements on the cup using a coordinate measuring device and micrometer measurements.

Results

Study I: It was shown that the method had a significantly higher accuracy than expected from routine radiography in detecting acetabular cup migration, giving both visual and numerical correlate.

Study II: The two examiners were able to differentiate between 0 mm, 1 mm and 2-3 mm cup migration with 100% specificity and sensitivity. Numerically intra- and inter-observer 95 % accuracy and repeatability limits were 0.5/0.7 mm respectively.

Study III: Reorienting the pelvis in image postprocessing was shown to be accurate and had a precision of 1° for the model and 1.5° for the patients. It enables

measurements relative to the pelvis and minimizes the dependence on patient positioning.

Study IV: Accuracy of the wear measurements expressed as penetration depth were ± 0.6 mm and ± 1.0 mm for the two examiners respectively. Accuracy of wear measurements for remaining polyethylene was ± 1.3 mm and ± 1.0 mm for the two examiners respectively. The method allows for accurate wear detection at a clinically relevant level. Measurements of remaining polyethylene were slightly less reliable than penetration depth, due to metallic artefacts.

Conclusions: These four studies present the basic principles of a new CT method, combining volume registration of CT data for migration detection, and landmarking of the prosthetic components to get a numerical correlate to migration and wear detection. It also offers validation of a locally developed image post processing tool for standard orientation.

Both migration and wear detection were shown to be improved with this new CT method, when compared to the use of conventional radiographs in clinical routine.

The locally developed tool for reorienting the CT volume in postprocessing was shown to be accurate and precise, enabling measurements relative to the bone or other chosen structure in the volume and minimizing the dependency on patient positioning.

LIST OF PUBLICATIONS

This thesis is based on the following publications, referred to in the text by Roman numerals I-IV. The contents were reprinted with kind permission from the respective copyright holders.

- I** Olivecrona L, Crafoord J, Olivecrona H, Noz ME, Maguire GQ Jr, Zeleznik MP, Svensson L, Weidenhielm L. Acetabular component migration in total hip arthroplasty using CT and a semi-automated program for volume merging. *Acta Radiol* 2002; 43: 517-27.
- II** Olivecrona L, Olivecrona H, Weidenhielm L, Noz ME, Maguire GQ Jr, Zeleznik MP. Model studies on acetabular component migration in total hip arthroplasty using CT and a semi-automated program for volume merging. *Acta Radiol* 2003; 44: 419-29.
- III** Olivecrona L, Aspelin P, Weidenhielm L, Stark A, Noz ME, Maguire GQ Jr, Zeleznik MP, Svensson L, Olivecrona H. Standard orientation of the pelvis: validation on a model and in 10 patients. *Acta Radiol* 2005;46:74-82.
- IV** Olivecrona L, Jedenmalm A, Aspelin P, Weidenhielm L, Noz ME, Maguire GQ Jr, Zeleznik MP, Olivecrona H. Assessing wear of the acetabular cup using computed tomography: an ex vivo study. *Acta Radiol* 2005; 46: 852-57.

CONTENTS

1	Introduction.....	1
2	Aims.....	5
3	Material and Methods.....	7
3.1	Material.....	7
3.1.1	Patients and implants: Studies I and III.....	7
3.1.2	Pelvic model: Study II and III.....	7
3.1.3	Explanted cups: Study IV.....	7
3.1.4	Examiners.....	7
3.1.5	CT examination and image volumes.....	8
3.1.6	Image registration tool (hardware).....	8
3.1.7	Image registration tool (software).....	9
3.1.8	Standard orientation module.....	10
3.1.9	Mathematical module.....	11
3.1.10	Coordinate measuring machine.....	11
3.1.11	Micrometer.....	11
3.2	Methods.....	11
3.2.1	Images analysis process.....	11
3.2.2	Statistical evaluation.....	16
4	Summary of Studies and Results.....	19
4.1	Study I. Acetabular component migration in total hip arthroplasty using CT and a semi-automated program for volume merging.....	19
4.1.1	Findings.....	20
4.1.2	Comments.....	20
4.2	Study II. Model studies on acetabular component migration in total hip arthroplasty using CT and a semi-automated program for volume merging.....	20
4.2.1	Findings.....	21
4.2.2	Comments.....	21
4.3	Study III. Standard orientation of the pelvis: validation on a model and in 10 patients.....	22
4.3.1	Findings.....	22
4.3.2	Comments.....	23
4.4	Study IV. Assessing wear of the acetabular cup using computed tomography: an ex vivo study.....	23
4.4.1	Findings.....	23
4.4.2	Comments.....	24
5	Discussion.....	25
6	Conclusions.....	27
7	Acknowledgements.....	29
8	References.....	31

Acronyms and Abbreviations

CAD	computer aided design
CT	computed tomography
EBRA	Ein-Bild-Roentgen-Analyse
ex	examiner
KS-test	one sample Kolmogorov-Smirnov test of composite normality
RE	reverse engineering
RSA	radiostereometry
SIAS	spina iliaca anterior superior
3D	three-dimensional
THA	total hip arthroplasty
TP	tuberculum pubicum
2D	two-dimensional

1 INTRODUCTION

In 1979 the Nobel Prize in Medicine was shared by two pioneers of computed tomography (CT), Godfrey Hounsfield, an engineer with EMI Ltd., and Allen Cormack, a South African medical physicist. EMI Ltd, the commercial developer of CT, was the first company to enter CT on the market. They did so only after offering the rights to sell, distribute, and service CT to the major vendors of imaging equipment. The vendors rejected EMI's offer because they believed the market for CT was too small.

EMI's first scanner, installed in 1973, was designed exclusively for studies of the head. The first whole body CT scanner was installed in 1975. And already by 1977, 16 or so commercial companies marketed more than 30 models of CT scanners[1]. Today, 30 years later, it is difficult to think of a hospital without at least one CT scanner.

The first and second generation CT scanners, acquired one slice at a time (Single slice CT scanners) using either a pencil or a fan beam, a single detector and a combination of rotation and translational movements.

Third and fourth generation CT scanners allow the gantry to rotate while the couch with the patient moves without stopping. (Spiral or Multislice CT scanner) The third generation used a fan x-ray beam and smooth rotation of the x-ray tube and detector array and fourth generation CT scanners have rotational motion of the x-ray tube within a stationary circular array of detectors of 600 and more.

The development of CT scanners, giving a refined spatial resolution in both axial and longitudinal plane, has enabled a transition from evaluating individual CT images to assessing entire CT volumes, either in 2D or in 3D.

Software development in the CT scanners used today have also reduced, though not yet eliminated, the image artefacts caused by metal; thus CT evaluation of prostheses is becoming more and more feasible.

Total hip arthroplasty (THA) is said to be one of the most cost-effective operations ever introduced[2]. In Sweden osteoarthritis is the main cause for THA operation. In the five year period of 1996-2000 the mean national incidence for a primary THA operation due to osteoarthritis was 90/100 000, constituting 76 % of all primary THA in that period[3].

In the follow up of THA operations radiological evaluation has an important role to play. Two long term complications that need to be assessed are migration/loosening and wear of the implant.

Another question to be assessed after a THA is the position of the implant, for the acetabular component usually described by cup anteversion and inclination.

The main problem in using conventional planar radiography is the fact that both migration and wear, as well as position, are three-dimensional (3D) problems but planar radiography is a two-dimensional (2D) method. This means that changes in patient positioning, differences in film-focus distance and different location of the central beam in the series of examinations will cause a lack in comparability between the radiographs[4].

There are several planar radiographic methods for assessing migration and wear of the acetabular cup in the frontal plane, based on direct measurements on anterior-

posterior radiographs. In a precision study under ideal conditions precision of the Nunn and of the Sutherland method approached a ± 1 mm level in assessment of acetabular migration. In a longitudinal study, however, these methods did not reach this detection limit, probably because of larger differences in patient positioning[5]. In a model situation the minimal apparent migration caused by different positioning of the pelvis was shown to be 2 mm for 5° of rotational malpositioning[6]. On routine clinical radiological follow up, using a series of conventional planar radiographs, a migration of approximately 5 mm of the cup is needed for detection[7].

To overcome this problem, planar radiography methods with a higher accuracy, have been developed. A clear cut level for clinically relevant accuracy and precision is difficult to establish but a desired detection level of 1 mm has been proposed[8].

If we accept 1 mm as the desired detection level of migration only two planar radiographic methods are currently available; Radiostereometry (RSA) and Ein-Bild-Roentgen-Analyse (EBRA).

RSA is a high-precision method that traditionally requires tantalum markers inserted into the prosthetic components as well as in the surrounding bone. However, it has more recently been shown that even without implant markers wear measurement of hip prostheses as well as assessment of migration of the femoral component, could be made with RSA[9][10].

In RSA two x-ray tubes, angled approximately 40° in relationship to each other, are used for simultaneous exposure, and a calibration cage with tantalum markers is placed between the patient and the film. This setting, together with dedicated software, allows for computing the 3D coordinates of the tantalum markers in the implant and bone of the patient, referred to the 3D coordinate system of the calibration cage, making a 2D method become 3D, mathematically. On a follow up examination the new coordinates of prosthesis and bone (in the coordinate system of the calibration cage) are compared to the previous ones. Migration and wear can then be expressed as differences in their (mathematical) positions between examinations. The precision of RSA varies between 0.15 and 0.6 mm in evaluation of hip prostheses [11].

RSA assesses both wear and migration in 3D. It is accurate and precise, but complicated and sometimes invasive. It gives a numerical but no visual output and has been considered suitable mainly for small patient groups in research settings.

EBRA is another computerized method that can be used for measuring implant migration and wear. A grid of transverse and longitudinal tangents on prominent landmarks of the pelvic contour are created on anterior-posterior radiographs of the pelvis. The EBRA software includes an algorithm to exclude radiographs with more than a set level of positioning or rotational error, getting fewer but more comparable radiographs. In the original method landmarks were placed on planar radiographs using a pencil and a ruler, and were then entered into the software using a digitizing tablet. This input method is now replaced by computer-assisted markings on digitized radiographs. The detection level of acetabular cup migration and wear with EBRA is approximately 1 mm[12][5][4][13].

For the assessment of wear several planar radiology methods, both manual and computerized, are reported to reach the detection level of 1 mm. One manual method was described by Livermore et al in 1990, where measurements by calipers made on post-operative AP radiographs are compared to measurements made on follow-up examinations [14].

In Martell's method (Hip Analysis Suite) of computer-assisted vector wear analysis, edge-enhancement is used to find the circles that best fit the femoral component head and a metal backed acetabular cup, comparing postoperative radiographs with later follow-up, digitized pelvic AP radiographs[15][16]. There is also a method described by Devane (PolyWare) where selected points from the standard AP and lateral pelvic radiographs are digitized manually and a 3D model of the acetabular component and femoral head is created. This model is then rotated to a standard frontal view. By comparing the images from initial post-operative and later follow-up examinations the displacement of the femoral head within the acetabular cup is measured. Also, the orientation of the acetabular cup (tilt and anteversion) could be assessed[17][18].

For acetabular component position, beside the problem of comparability of radiographs, there are also three different definitions of cup anteversion and inclination in use – the radiographic, the operative, and the anatomic – corresponding to the different situations where the orientation is measured[19][20], and these different measurements are not easily converted between the systems. Beside planar radiographic methods, CT has been used to measure acetabular cup anteversion on single axial slices, measuring anteversion, in the coordinate system of the CT scanner[21]. CT has also been used in pre-operative planning for image guided navigation systems in computer assisted surgery[22][23].

As has previously been shown by our research group that it is possible to accurately assess implant position and orientation in 3D with CT, by placing landmarks on the acetabular cup and femoral component head[24][25]. From these landmarks the direction of the acetabular axis (the vector perpendicular to the cup face) can be calculated, using mathematical algorithms. The acetabular axis can then be expressed as inclination and anteversion in any of the three systems mentioned above (operative, radiographic, or anatomical) and, if the image volume of the pelvis is also rotated to a standardized orientation, measurements of implant orientation can be made relative to the bone rather than to the coordinate system of the CT scanner[26].

To date RSA is considered the most exact method to assess both wear and migration in 3D. As stated earlier, it is accurate and precise, but also complicated and perhaps invasive and while it gives a numerical output, it gives no visual output and thus is considered useful mainly for small patient groups in research settings.

Therefore, a truly 3D radiology method for evaluation of prosthetic migration and wear, with a higher detection level than conventional planar radiology, that gives both a visual and a numerical output, and still could be used in clinical practice, would be desirable.

In attempting to achieve this we choose to test the combination of 3D CT data together with volume registration, also called volume merging. Volume registration is the process of bringing data from two different image volumes into spatial alignment and it will ideally eliminate any positional difference between the volumes. If the pelvis in two different CT scans from the same patient are registered, and the malpositioning eliminated (ideally), a remaining difference in position of the acetabular cup would then be a sign of altered position between the two scans, indicating migration or loosening. In order to achieve a numerical as well as a visual correlate to migration and to measure wear, the prosthetic components would need to be landmarked in much the same way as when evaluating the orientation of the implant[24][25]

2 AIMS

These studies were a part of a development project for a non-invasive method for accurate routine evaluation of orthopedic implants, based on CT.

Overall aims: to develop and test a new CT method for evaluation of orthopedic implants – using the pelvis, acetabular cup, and femoral component head as a model system.

In the separate studies the following objectives were addressed:

- Study I A strategy for evaluating migration of orthopedic implants, using volume registration of CT 3D data sets combined with volumetric detection of the implant, was devised and tested. The aim was to test if the pelvis could be registered in the presence of THA, and if more accurate numerical and visual results, than would be expected from routine radiographs, could be obtained, using a minimal detection pattern for the prosthesis.

- Study II The CT-method for evaluating migration of orthopedic implants, from Study I, was further validated in a blinded phantom study, using true migration of an uncemented acetabular cup.

- Study III A locally developed post processing tool for rotating the CT volume of the pelvis into a standard orientation, was validated calculating precision and accuracy. It was also tested if a pelvic standard orientation allowed for correct measurements of known acetabular cup migration vectors from the model study (Study II).

- Study IV A clinically useful CT-method for assessing wear of the acetabular cup was locally developed and validated in an ex vivo study.

3 MATERIAL AND METHODS

3.1 MATERIAL

3.1.1 Patients and implants: Studies I and III

Ten patients who had undergone primary THA replacement with a Charnley implant system (Depuy; Warsaw, IN, USA) were included.

In the Charnley implant system the acetabular component, the cup, is made of polyethylene. To facilitate radiological evaluation it also has a metal thread bent into two hemicircles. One hemicircle is designed to be parallel to the plane of the cup face. The other is bent at approximately 90° going over the cup hemisphere, and is designed to be parallel to the acetabular axis. The acetabular axis is the axis perpendicular to the cup face, and passing the center of the cup face.

3.1.2 Pelvic model: Study II and III

A plastic model of a human pelvis (Sawbones, Vashon, WA, USA) was mounted on a Plexiglas plate. Spina iliaca anterior superior (SIAS) and the tuberculum pubicum (TP) on both sides were placed in a horizontal plane, parallel to the Plexiglas plate and the tuber os ischii were placed in a plane perpendicular to the Plexiglas plate. Since the plastic pelvis did not have bony structures to landmark spherical tantalum markers were inserted in the pelvic model, evenly spread.

A hemispherical titanium alloy acetabular prosthetic cup (Trilogy, Zimmer, Warsaw, IN, USA) was mounted on a stainless steel guide rod, and placed on a sliding Plexiglas device that allowed fixed movements along the cardinal axes of the pelvis: axial (head-toe), coronal (anterior-posterior) and sagittal (left-right). 1 and 2 mm Plexiglas shims were used to achieve reproducible translations.

3.1.3 Explanted cups: Study IV

In Study IV eight explanted cups with matching 28 mm femoral component head (Romanus; Biomet, Warsaw, IN, USA) that had been used in patients and then removed, were used. A Romanus acetabular cup consists of an hemispherical titanium alloy shell, a polyethylene liner, and a hexagonal locking device.

3.1.4 Examiners

For Studies I, II, and IV

Two examiners (resident in radiology and specialist in orthopedic surgery), performed the image analysis independent of each other.

For Study III

The image analysis was performed by one examiner (resident in radiology). In addition to this, data from a previous study where the image analysis was performed by two

examiners (one resident in radiology and one specialist on orthopedic surgery) were reevaluated.

3.1.5 CT examination and image volumes

Studies I and III

A Picker PQ5000 fourth generation spiral CT unit was used to examine the ten patients. During their first postoperative week two CT scans were obtained from each THA patient. Between the scans the patient rose from the CT table and was repositioned.

Images were acquired with 5 mm collimation and a pitch of 2, at 175 mA, 120 kV from the iliac crest to the tip of the prosthetic stem, except for over the cup where 2 mm collimation and 200 mA was used. Images were reconstructed with 5 mm increment (above and below the cup) and 1.5 mm increment (over the cup). The radiation dose for the scan was 0.8 mSv. In Study I only the slices around the cup were used and for Study III the whole volume was used.

Studies II and III

The pelvic model was examined using a LightSpeed QX/I fourth generation CT unit (General Electric Medical Systems, Milwaukee, WI, USA).

The model was scanned with the cup in 16 different positions relative the pelvis. It was scanned twice for the first ten cup positions, and once for the remaining 6 cup positions. Between all scans the position of the model was altered to simulate different patient positioning.

Images were acquired with 1.25 mm collimation and a pitch of 3 (0.75 mm/rotation) at 250 mA, 120 kV from the iliac crest to the tuber os ischii. Images were reconstructed with 1.25 mm increment.

In Study II, the resulting 26 different CT scans were combined to produce 37 cases (CT volume pairs) with 0 – 3 mm migration and given random numbers.

For Study III, twenty-four of the original 26 CT volumes of the pelvic model were used. (two volumes that did not include all pelvic parts needed for the pelvic standard orientation were excluded).

Study IV

The eight explanted cups were examined with a LightSpeed QX/I fourth generation CT unit (General Electric Medical Systems, Milwaukee, WI, USA).

Two scans of each cup were acquired, altering the cup's position between the scans.

Images were acquired with 1.25 mm collimation and a pitch of 3 (0.75 mm/rotation) at 40 mA, 120 kV. Images were reconstructed with 1.25 mm increment.

3.1.6 Image registration tool (hardware)

In Studies I and II a stationary workstation (C3000, Hewlett-Packard, Palo Alto, CA, USA) was used. Study III-IV were performed on a laptop computer (Precision M50, Dell Computer Corporation, Austin, Tx, USA). Since these studies were made in the

late 1990's and beginning of the 2000's by today's standards, the computers had a very limited capacity. To speed up the data processing we therefore simplified the resolution from the original 512 x 512 to 256 x 256 voxel images.

3.1.7 Image registration tool (software)

We have been using a locally developed image registration tool. The registration algorithm incorporated in this tool has been previously extensively validated [27][28][29][30][31][32].

It can be used to produce an affine or non-affine (warping) transformation in which the transformation coefficients (eigen-values) are derived from manually picked point pairs. However in this thesis only the affine transformation was used.

The user interface of this tool can present the images from the reference volume and the volume to be transformed in one of the three planes (axial, coronal, or sagittal slices) in two larger views. Alternatively six smaller views with corresponding slices in all three planes can be used.

There are two window width/level settings. In these studies we used a lower window for viewing the skeletal structure and a higher window to simultaneously view the high attenuating metal in the cup or cup thread, the femoral component, or the tantalum balls in the pelvic model. Figure 1 illustrates the user interface.

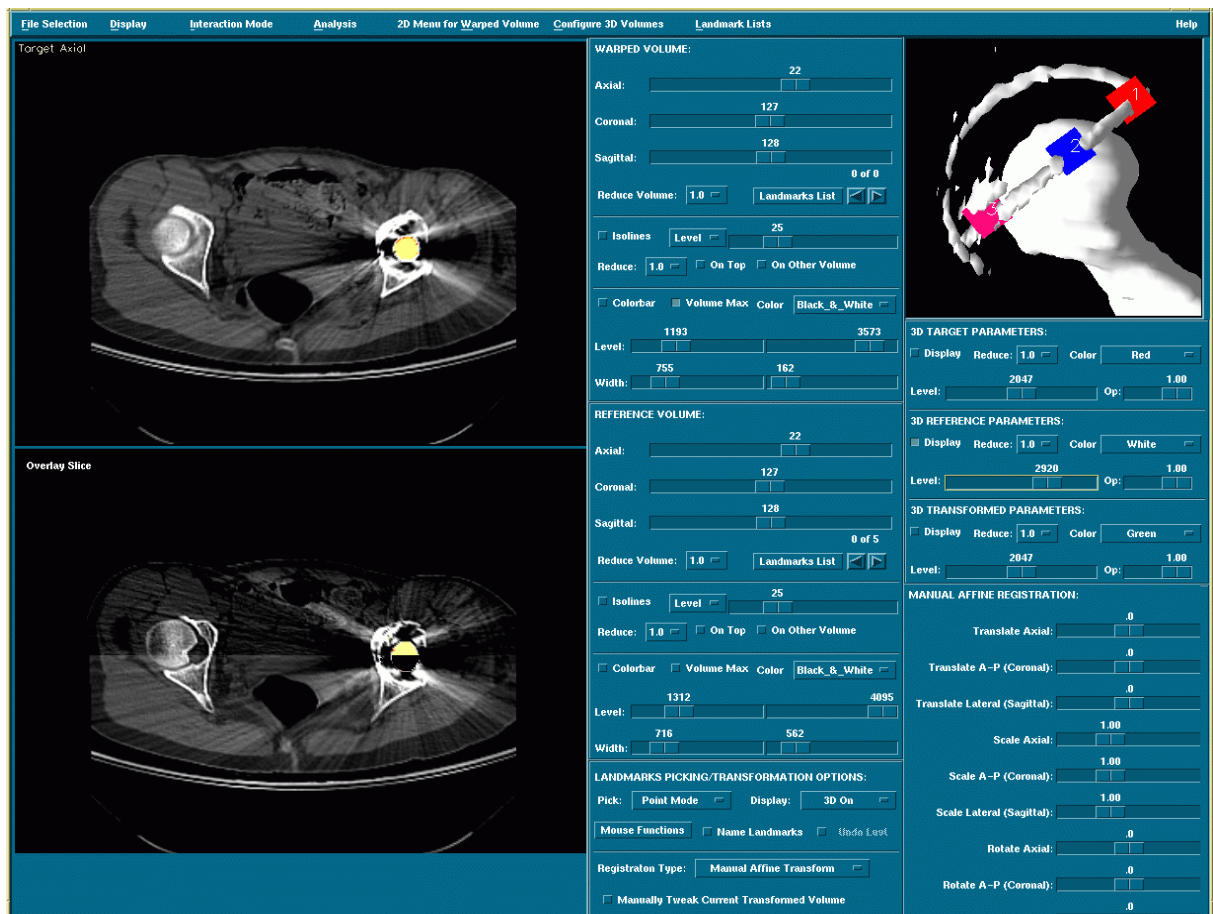


Figure 1: User interface of the image registration tool showing reference volume in the top left window and overlay of reference and transformed volume in bottom left window. Also a 3D iso

The point pair needed for the transformation, is obtained by landmarks chosen on concurrently viewed slices that display the same skeletal structure or tantalum ball, in the reference volume and the volume to be transformed (target volume). When a landmark is chosen the corresponding volume element, independent of voxel, is marked and a sequential number is generated. All landmarks are recorded at their respective 3D point in distance units, mm in this case.

Landmarking can be performed either with point landmarks or with a sphere landmark, if the structures to be landmarked are spherical, for example the tantalum balls implanted in the plastic pelvic model. The sphere landmark superimposes the contour of a true 3D sphere on the images in all three planes (axial, coronal, and sagittal) together or separately. The sphere is moved into the correct position in the volume by positioning the computer pointer within the sphere contour and dragging it into place. When the sphere is moved into a satisfactory position the user generates a landmark representing the 3D coordinates of the sphere center. The sphere size can be altered either by specifying the radius or by re-sizing the sphere with the computer's pointing device.

The paired 3D landmarks are then used to create the transformed volume through an affine transformation. This new volume can be re-sliced and evaluated side by side with the original reference volume in any of the three planes. The transformed volume can also be superimposed on (fused with) the reference volume. These features were used to visually check the matching of the pelvis and the prosthetic components of the two volumes.

A 3D isosurface of the transformed volume may also be displayed, superimposed with an isosurface of the reference and/or target volume. These 3D volumes can be rotated and viewed from an arbitrary direction. In Study II it was used as another way to visually evaluate the prosthetic migration.

There is also a completely manual affine transformation (translate, rotate, and scale) available in the software, which was used in Study I to create images showing migration.

3.1.8 Standard orientation module

To be able to bring the CT volume of the pelvis from the orientation in the CT scanner to a standardized pelvic orientation, a standard position module was locally developed and added to the existing image registration tool.

The strategy of a pelvic standard orientation utilizes the fact that the pelvis has a well-defined coronal plane through the superior iliac spines (SIAS) and the pelvic tubercles (TP) [33][34][35], here referred to as the Mc Kibbin plane. Orthogonal to the Mc Kibbin plane is a plane through the left and right tuber os ischii.

In a special standard orientation window on the screen a 3D isosurface of the CT volume of the pelvis is brought up first in an axial view. The 3D volume can be rotated, scaled, and viewed from an arbitrary direction. Dragging the mouse over the screen allows the CT volume to be rotated, either around one specific screen axis or in all directions simultaneously. A movable horizontal line is superimposed over the image to aid in alignment.

When satisfied with initial placement, a menu button can then be used to rotate the volume 90° clockwise or counter-clockwise around the screen's left-right axis,

changing between axial and coronal view. After the standard orientation is completed the angular result of the rotation is saved in matrix form. The transformed volume is also saved in standard orientation.

3.1.9 Mathematical module

Together with X3D Medical AB a mathematical module was developed. The mathematical module autogenerates the 3D coordinates for the sphere center using coordinates from point landmarks placed on the sphere surface.

3.1.10 Coordinate measuring machine

In cooperation with KTH a coordinate measuring machine (CMM) (LH44 Wenzel, Wiesthal, Germany) was used to assess wear as linear penetration depth, together with the locally developed mathematical module above.

3.1.11 Micrometer

A digital micrometer was used (IP 54 Giga, China) in assessment of the remaining polyethylene.

3.2 METHODS

3.2.1 Images analysis process

Migration detection: Study I and II

The strategy for migration detection in Study I and II is based on regarding the pelvis and the prosthesis as two rigid bodies that are supposed to be immobile in relationship to each other. If a movement between the two bodies on two different CT examinations can be detected visually or numerically the prosthesis is considered to be loose or migrating.

To be able to detect movements between the two bodies in two different CT scans, one of the rigid bodies (the pelvis) in the first examination is brought into spatial alignment with the same rigid body in the second CT examination, through the process of image registration. The other rigid body (the prosthesis) is then visually and numerically examined for migration between the CT scans.

The image registration is performed by viewing the two CT volumes, the reference volume and the target volume in two parallel windows. Landmarks are then placed on CT slices from the two examination that show the same physical structure. When a sufficient number of landmarks have been placed (generally around 10) a transformed volume is created. The new transformed volume can then be viewed together (separately, side-by-side, or superimposed (fused)) with the reference volume and the degree of matching evaluated. If the mismatch was less than one cortical width in Study I and less than 1 mm in Study II the matching was considered adequate.

Visual evaluation

When the image registration of the pelvis is completed the prosthesis can be evaluated for migration visually. If there is no migration between bone and prosthesis between examinations the prosthesis in the two examinations should be registered to the same degree as the pelvis. However if there is migration there should be a greater mismatch of the prosthesis compared to the pelvis in 2D overlay images. In the 3D isosurface display the prosthesis from the two examinations are each given a different color, for example red and white. In a perfect match the colors would blend to pink. In a reasonably good match the colors would mix in patches and in a bad match or a migration the colors would separate.

In Study I, where there was no true migration, we aimed at creating a correlate to migration by performing manual affine transformations on one of the matched volumes. From a refined match translations of ± 1 mm along the cardinal axes were created and viewed as 3D isosurface overlays. To assess the visual correlate to a perfect match we performed the same experiment using the same CT volume as both reference volume and target volume decreasing the translations to ± 0.5 mm respectively. Finally we chose a medium match and made translations of 2 mm and 5 mm as comparison with the precision expected by routine planar radiography[7].

In Study II, there was true migration of the cup, and after the matching of the pelvis was considered adequate, the prosthesis was evaluated for migration in 2D and 3D overlay images. The two observers first had to make a decision between “migration” and “no migration” and then in case of “migration”, to subdivided each case into groups of either “1 mm migration” or “2-3 mm migration”. Figure 2 illustrates 2D and 3D visual evaluation.

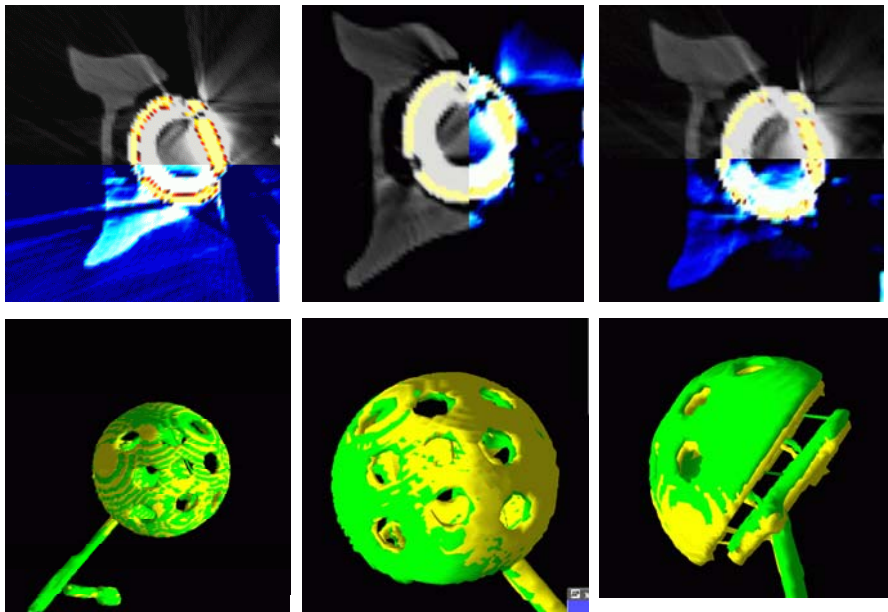


Figure 2: 2D and 3D overlays of 0 mm migration (left), 1 mm migration (middle), 2-3 mm migration (right).

Numerical evaluation

To also get a numerical correlate to the situation of migration or no migration, landmarks were placed on the prosthesis in the two examinations.

In Study I, a sphere landmark was placed on the head of the femoral component. The sphere landmark automatically gives the 3D coordinate for the sphere center, in this case the center of the femoral head. For the acetabular cup three point landmarks were placed in the hemicircle of the thread parallel to the cup face. The 3 point landmarks were used to calculate the center point of the acetabular cup face and the acetabular axis. Two landmarks were placed on corresponding bony landmarks in the contralateral femur. Angular difference of the acetabular axis, distance between acetabular center points, difference between femoral head center points and distance between the mean of the center points in the contralateral femur were calculated.

In Study II landmarking of the uncemented acetabular cup, was extended to 20 point landmarks spread over the cup hemisphere and used to calculate the center of the corresponding sphere. From the distance between the cup center point in the two examinations the length of the migration vector was calculated.

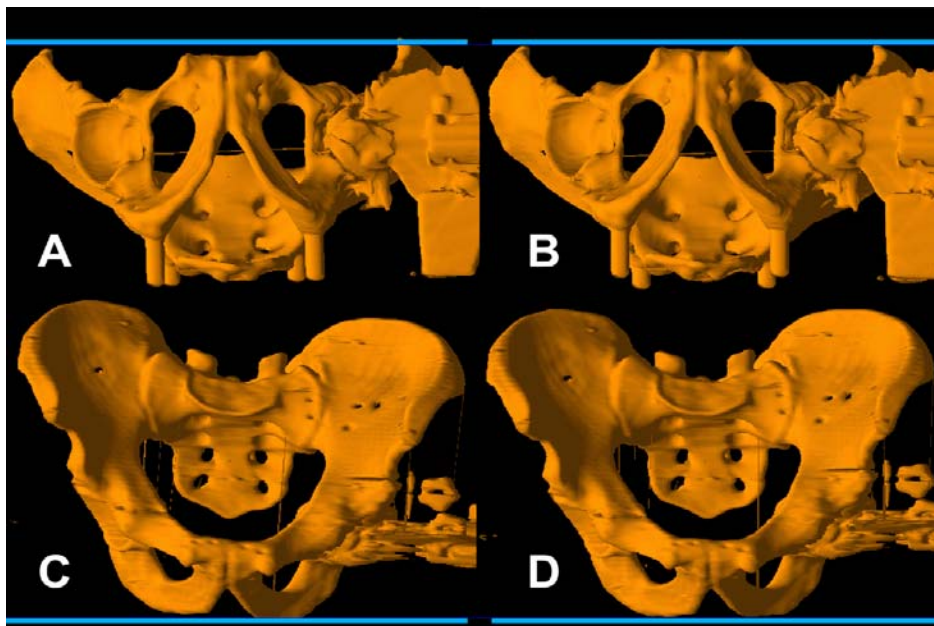


Figure 3: Sequence of pelvic standard orientation shown on the pelvic model.

Standard orientation: Study III

To place the CT volume of the pelvis in a standard orientation the CT volume is first displayed in an axial view. The left and right SIAS together with the left and right TP (the Mc Kibbin plane) are then aligned horizontally with the left- right screen axis. To check this and aid in the alignment a movable horizontal line is used. After this first alignment is completed the view angle is changed to coronal by a 90° rotation around the left-right screen axis. In the coronal view the tuber os ischii are aligned with the

left-right screen axis using the same horizontal line, thus aligning the CT volume of the pelvis with the screen axes. (See Figure 3.)

The mathematical matrices created by this (the rotation it would take to move the volume from original orientation to standard pelvic orientation) were used to evaluate precision and accuracy of the method.

Precision

To test the precision of the standard orientation tool the 24 CT volumes of the pelvic model were brought into pelvic standard orientation twice, with a one week interval, by the same examiner.

In a previous study [26], the 20 patient CT volumes had been brought into pelvic standard orientation twice, and one week apart, by two examiners. At that time we evaluated precision with respect to the acetabular axis, now we reevaluated the data, calculating the maximum error over all directions in the volume.

Accuracy

For accuracy the 3D sphere was used to place landmarks on three of the tantalum balls situated in the left and right SIAS and left TP in all the 24 volumes. Using the standard orientation tool these landmarks were first aligned horizontally in the axial view. The volume was then rotated 90° to a coronal view and the left and right SIAS were aligned horizontally, thus aligning the landmarks with the screen axes. This was done twice with a one week interval by one examiner.

Direction of migration vector

To apply the standard orientation procedure to a clinical problem, the migration vectors measured in Study II were rotated from the orientation in the CT scanner to the standard pelvic orientation. The direction of migration measured with and without the standard pelvic orientation was calculated and compared to direct measurements on the model. Six cases with no migration were excluded.

Wear detection: Study IV

Linear penetration depth

The implant used is truly hemi-spherical, and in a non-worn cup the centers of the cup and the femoral head coincide. For assessment of linear penetration depth sphere landmarks were placed on the femoral head and the outer surface of the cup shell and the 3D distance between center-points calculated. In a non-worn cup the center-points of these spheres would be identical, and the difference 0 mm. In a worn cup, however, the the femoral component head will move closer to the cup shell and a difference in center-point location will occur. The 3D distance between center-points will then represent the wear vector.

After the CT examination the polyethylene liners were examined with a coordinate measuring machine, using 8000 digitizing points. A sphere was fit to the

digitized points from both the un-worn and to the worn region (the wear tract) and the difference in radius calculated, giving the linear penetration depth.

Remaining polyethylene

Starting with the spherical landmark already placed on the femoral component head, another identically sized spherical landmark, was superimposed on the first. The second spherical landmark was then expanded, using the computer's pointing device, until it reached the inner surface of the cup shell. The difference in radii of the two spheres was calculated, as a representation of the remaining polyethylene.

In a test re-test procedure assessment of linear penetration depth and remaining polyethylene were performed twice, with a one week interval, on all volumes by the two examiners. This is illustrated in Figure 4.

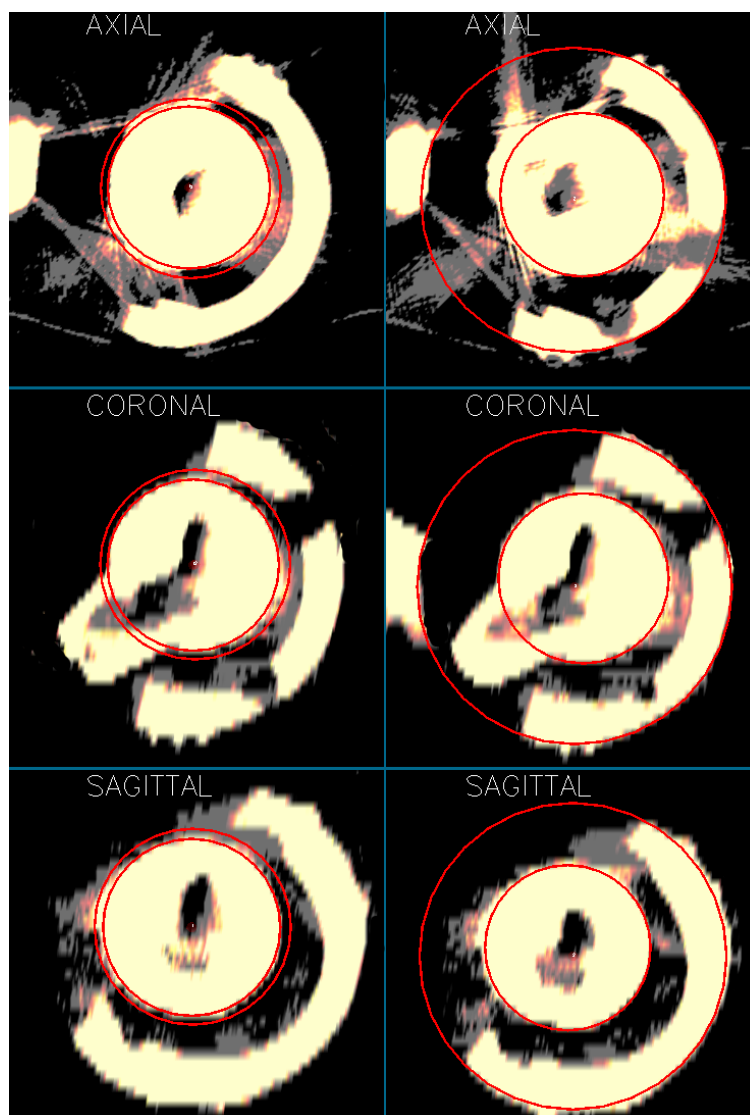


Figure 4: Wear measured as remaining polyethylene (left) and as linear penetration depth (right).

3.2.2 Statistical evaluation

Definitions [36][37]:

Accuracy limit	the value below which 95% of all errors are expected to fall assuming normal distribution and no bias.
Precision	the closeness of agreement between independent test results obtained under stipulated conditions.
Accuracy	the closeness of agreement between a test result and the accepted reference.
Bias	the mean difference between measurements in a series and the true value.
Trueness – the opposite of bias	the closeness of agreement between the average value obtained from a large series of test results and an accepted reference.
Repeatability	precision under repeatability conditions.
Repeatability conditions	conditions where independent test results are obtained with the same method on identical test items in the same laboratory by the same operator using the same equipment, within a short interval of time.
Repeatability limit	the value less than or equal to which the absolute difference between two test results obtained under repeatability conditions may be expected to fall in 95 % of random trials

Study 1

In addition to the visual evaluation of the matching of the pelvis, made by each examiner, we also performed a numerical evaluation of the matching using the resulting data from the landmarks as they were placed by examiner 1 and 2. ANOVA, analysis of variance on uneven datasets, was used and showed no significant differences in landmark placement within patients or across the set of patients.

Using a t-test we also compared the distance differences between the reference and transformed landmarks with the intravoxel distance in the CT scans. We found that the measurement error was within one CT voxel.

In addition to this we also compared the square sum of intensity differences for the reference/untransformed and the reference/transformed volumes, showing them to be significantly different. Visual inspection established this difference to be caused by better matching.

A t-test on the reference/untransformed and the reference/transformed volumes, of each patient individually, showed them not to be significantly different. Showing that

for all patients the malpositioning before image registration and alignment afterwards were about the same.

The normalized correlation coefficient of reference/untransformed and the reference/transformed volumes as well as the cross-correlation coefficient were higher after transformation than before transformation, indicating better matching.

Study II

The data was tested for normality using the Shapiro-Wilks goodness of fit algorithm. Repeatability and accuracy limits were calculated according to the definitions set by Ranstam[37].

A students t-test was used to analyze intra- and inter-observer differences. ANOVA, analysis of variance for uneven datasets with 6 groups, was performed on the 6 positions of 0, 1, 2, 3 mm migration single axis and 2.45 and 3 mm migration combined axes. ANOVA showed no differences between observers, but a significant difference between positions, with the largest errors for 0 mm migration and diminishing errors as the distance of migration increased. Examiners were consistent within and between the different position values. Histogram of residuals and plot of normal quantiles were used as graphical evaluation of normality.

Study III

Data were tested for normality using the Kolmogorow-Smirnov test (KS-test) as well as graphically using density plots and quantile-quantile plots. For all trials the data showed a slight departure from normality and therefore the Wilcoxon signed-rank test was used as a complement to the t-test.

Study IV

As in Study III data were tested for normality using the KS-test as well as graphically.

Accuracy, repeatability and bias of the CT method was calculated at the 95 % confidence level. Repeated measures ANOVA was used to evaluate differences between observers, trials and CT scans of the same prosthesis. For example, examiner 1 – trial 1 – scan 1 compared to examiner 1 - trial 1- scan 2, and so forth. (essentially three groups with eight cups – compared to another set of three groups with eight cups)

To include the errors of both CT acquisition and image post-processing, measurements of the same prosthesis, made on different days, on different CT scans, but by the same examiner, were also compared.

In the measurements of linear penetration depth no significant systematic differences between examiners, CT-scans, or trials were found. For measurements of remaining polyethylene there was a significant difference between examiners in assessing one of the CT scans, but no difference between scans or trials otherwise.

4 SUMMARY OF STUDIES AND RESULTS

4.1 STUDY I. ACETABULAR COMPONENT MIGRATION IN TOTAL HIP ARTHROPLASTY USING CT AND A SEMI-AUTOMATED PROGRAM FOR VOLUME MERGING

In this study a new strategy for evaluating migration of orthopedic implants was proposed.

Since migration essentially is a movement of one body in relationship to another on repeated examinations, the hypothesis was that volume registration of 3D CT data could eliminate the positional error and improve migration detection.

The study was exploratory, aiming to test if the pelvis from repeated CT scans could be registered in the presence of THA, and if the new method would outperform routine planar radiographs in migration detection.

Ten patients were scanned twice with CT. The repeated scans were acquired only 10 minutes apart, making it probable that no change in implant position would have occurred. Consequently, a successful registration of the pelvis would also register the acetabular cup, and head of femoral component.

For volume registration, landmarks were placed in corresponding points on axial CT slices of the pelvis by two examiners. Examiner 1 registering patient 1-5, and examiner 2 registering patient 6-10, both examiners used about 20-30 minutes on the process. After registration the match was checked visually and the registration repeated until the mismatch was one cortical width or less between the registered volume and the reference volume. When the match was considered adequate three point landmarks were placed in the hemisphere of the thread of the acetabular cup parallel to the cup opening. A spherical landmark was placed in the head of the femoral component.

For the 7 patients with unilateral THA two point landmarks were placed in the contralateral femur. These last two landmarks were expected to show random movement between the two CT scans.

To assess the method's visual sensitivity to migration, a patient with one of the best matched pelvis was chosen and the registration was further refined. From this "best possible registration" the registered volume was moved ± 1 mm along the three axes in respect to the reference volume. These six new volumes, together with the reference volume, were displayed as 3D-overlays and rotated into the position to where the position error between the cups in the reference and the moved volumes were most clearly seen. To assess the visual correlate of a perfect match, the same CT examination as both reference and target volume was used, the corresponding translations of the transformed image was decreased to ± 0.5 mm. Finally, to create a correlate to the accuracy that could be expected from routine radiographs[7], a patient with a typical match of the pelvis was chosen and movements of 2 mm and 5 mm in the axial direction of this volume were created in overlays.

For numerical evaluation a linear algebraic solution for computing the acetabular axis orientation and center-point of cup opening from the cup landmark data was described and used. Differences of acetabular axes orientation, positions of the center of the cup opening and prosthetic femoral head, along with the mean of the two points

in the contra-lateral femur across the two patient volumes after fusion were calculated in 3D and expressed as magnitudes.

4.1.1 Findings

Volume registration of the pelvis could be attained in all patients, within a clinically reasonable time frame of up to 30 minutes. Visual evaluation showed that from a perfect match a translation of 0.5 mm in any direction was clearly visible as a color separation between the transformed and the reference volume. In a 'best possible match' there was color overlapping but still some visual non-matching of the threads, indicating a quite accurate, but not perfect, registration. From this "best possible match" translations of 1 mm along any cardinal axis created a clear separation of the thread colors. Moving one of the volumes of a "medium match" 2 or 5 mm in the axial direction caused distinct separation, not only of colors but of the threads. For comparison, none of the 10 cases showed a thread separation.

Numerical evaluation showed mean error in the angle between cup openings of 2.5°, mean error of acetabular opening center-point of 2.5 mm, and mean error of femoral component head 1.0 mm.

4.1.2 Comments

The sample size was small, and done with an outdated CT technique. One patient had significant movement artifacts of the pelvis in one of the volumes, another patient had only about a quarter-circle of the thread visible in one of the scans.

Nevertheless the study showed that even in presence of a THA registration of CT volumes is possible. In a clinically reasonable time frame, CT volumes of the pelvis could be registered to within approximately 1 mm.

Registration of the pelvis allows for visual evaluation of cup position and the experiments with manual affine transformations clearly indicate that small movements that would normally go undetected using routine radiographs would be detectable with this method.

Numerical analysis indicated that, using volumetric detection of the cup, even with a minimal pattern for cup and femoral head landmarks, the detection level is below 1 voxel and would outperform what could be expected from routine radiographic follow-up.

The radiation dose of the CT examination was quite low, only 0.8 mSv.

4.2 STUDY II. MODEL STUDIES ON ACETABULAR COMPONENT MIGRATION IN TOTAL HIP ARTHROPLASTY USING CT AND A SEMI-AUTOMATED PROGRAM FOR VOLUME MERGING

In this study the above method for migration detection, using CT and volume registration, was further validated in a blinded phantom study, with true migration of an uncemented acetabular cup.

A plastic model of a human pelvis, with 1 mm tantalum markers evenly spread through the volume to mimic a bony structure, was mounted on a Plexiglas plate.

A hemispherical titanium alloy acetabular cup mounted on a stainless steel guide rod was placed on top of a sliding Plexiglas device that allowed fixed movements along the axial, coronal and sagittal axis.

Twenty-six CT scans of the model with the cup in 16 different positions were acquired, altering the position of the model slightly between each scan to simulate different patient positioning. These 26 CT volumes were then combined to create 37 cases (= pairs of CT volumes) with 0 mm, 1 mm, 2 mm, 2.45 mm and 3 mm migration of the acetabular cup, and randomly numbering them from 1 to 37 to blind the examiners.

Two examiners each evaluated all 37 cases. For volume registration, 3D spherical landmarks were placed corresponding to the tantalum markers in the two volumes of each case, using the simultaneous axial, coronal, and sagittal view option. Registration of the pelvis was visually inspected, and if the mismatch was less than 1 mm, registration of the pelvis was considered adequate. After registration, the matching of the two acetabular cups were visually checked in 2D and 3D overlays. The examiners first made a decision between “migration” and “no migration.” They then further divided the cases that showed “migration” into groups of “1 mm migration”, and “2-3 mm migration” respectively.

For numerical evaluation a second set of 20 point landmarks were placed on the cup surface in the two volumes of each case. The 20 cup landmarks were used to calculate a best fit sphere with the center-point M. The difference in position between the cups, the “migration”, was calculated as the 3D distance between M for the two volumes. The calculated best fit spheres could also be viewed in 3D images.

4.2.1 Findings

Visually the examiners differentiated between the groups of 0 mm, 1 mm, 2-3 mm migration in all 37 cases with 100% sensitivity and specificity. Numerically 95% intra- and inter-observer accuracy limits were below 0.5 mm and, 95% intra- and inter-observer repeatability limits were below 0.7 mm with no inter-observer differences.

4.2.2 Comments

In this study tantalum markers in a plastic pelvis were used for volume registration. The markers however, cause a zone of metal artefact and were not necessarily easier to landmark than the normal bony structure of the pelvis we previously used for the registration.

The 100 % sensitivity and specificity for visual detection of migration indicate that the detection limit probably is below 1 mm in this ideal situation. When designing the study we unfortunately assumed that the detection limit would be above 1 mm, and therefore did not test for smaller migrations.

For the numerical evaluation we choose to keep the number of cup landmarks within clinical feasibility, and this study does not provide data on the absolute detection limit of the method.

Still the results of this method, both visually and numerically, exceed those of routine planar radiographs.

4.3 STUDY III. STANDARD ORIENTATION OF THE PELVIS: VALIDATION ON A MODEL AND IN 10 PATIENTS

To be able to relate measurements of directions made in a CT volume of the pelvis, to the bone rather than to the coordinates of the CT scanner, a post processing tool for rotating the CT volume of the pelvis into a standard orientation, was locally developed. In this study we validated this standard position tool, calculating its precision and accuracy. We also tested if a pelvic standard orientation allowed for correct measurements of known acetabular cup migration vectors from the model study (Study II).

For precision (precision = the closeness of agreement between independent test results obtained under stipulated conditions), 24 of the 26 CT volumes from Study II (two scans that missed bony parts needed for the standard orientation were excluded) were rotated to the defined pelvic standard orientation by one examiner who repeated the process after 1 week. The rotations were recorded and the maximum rotation errors between trial 1 and 2 were calculated.

In a previous study [26], the paired patient scans in Study I were rotated to a pelvic standard orientation by two examiners and the process repeated after one week. In the previous study the acetabular axis in the volumes was studied. We now reevaluated these data with respect only to the precision of the standard orientation procedure, calculating the maximum rotation error between trials and examiners.

To determine accuracy (accuracy = the closeness of agreement between a test result and an accepted reference) three sphere landmarks were placed on tantalum markers situated in left and right SIAS and left TP in the 24 volumes. The standard position tool was then used to align the landmarks with the cardinal axes of the screen. The difference between measured and actual screen coordinate axes were then calculated for each volume. Since this difference is a forced positive value we also calculated trueness (trueness = the closeness between the average value of a large amount of test results and the accepted reference) of the landmark reorientation procedure. The average measured coordinate system was calculated and compared to the screen coordinate system.

Also, data on migrational vectors from Study II was reevaluated, to test if a standard orientation would improve assessment of the direction of migration. 30 of the original 37 cases were used, excluding six cases with no migration.

4.3.1 Findings

Precision was better than 1° in the model study and better than 1.5° in the patient study.

Accuracy, expressed as angle between ideal and measured coordinate axes was below 0.1° for x,y,z axes.

Trueness was 0.02° for the x, y, and z axis and 0.04° along the axis of maximum rotation in the volume.

No systematic errors were found.

Comparing the acetabular cup migration vectors before and after pelvic standard orientation, no significant differences were found.

4.3.2 Comments

With a precision below 1° in a test-retest situation, accuracy of below 0.1° and a trueness of 0.02° for all axes, the standard orientation tool could be considered a precise system with only random errors.

Including a pelvic standard orientation showed no significant effect on the direction of the acetabular migration vectors. This was possibly due to the fact that the migration vectors were small and the error in detection of the two cup centers were probably greater than the actual malpositioning of the model. Also, the model was built with the frontal plane (Mc Kibbin plane) parallel to the supporting Plexiglas plate, and the pelvic inclination in patients was therefore not reproduced.

4.4 STUDY IV. ASSESSING WEAR OF THE ACETABULAR CUP USING COMPUTED TOMOGRAPHY: AN EX VIVO STUDY

In this study we validated a locally developed CT-method for assessing wear of the acetabular cup.

Eight uncemented cups with corresponding femoral components that had been removed from patients were used. Two CT scans, in slightly altered positions, were obtained of each cup. External pliers were used to hold femoral component head in the cup during the CT examination.

In the images analysis the linear penetration depth of the femoral component into the cup and the thickness of the remaining polyethylene were measured in the CT volumes.

For linear penetration spherical landmarks were fitted to the outer contour of the prosthetic femoral head and of the acetabular cup to determine the coordinates of their center-points. The implant used is spherical, and in a no wear situation the center-point of the cup will coincide with that of the femoral component head. Therefore the distance in 3D between center-point of cup and femoral component could be used to calculate the linear penetration depth.

To assess the remaining polyethylene we used the above spherical landmark already fitted to the femoral component head. A second identically sized landmark was placed on the first and then expanded until it reached the inner surface of the cup shell. The difference in radii between the two spheres was calculated as a representation of the thickness of remaining polyethylene.

Each CT volume was examined twice by two examiners, using approximately 5 minutes per scan. The CT measurements were then compared to direct measurements on the polyethylene liner using a coordinate measuring machine (CMM) and micrometer measurements.

4.4.1 Findings

Accuracy of the wear measurements expressed as penetration depth was ± 0.6 mm and ± 1.0 mm for the two examiners respectively. Accuracy of wear measurements for remaining polyethylene was ± 1.3 mm and ± 1.0 mm for the two examiners respectively. In the measurements of linear penetration depth no significant systematic differences

between examiners, CT-scans or trials were found. For measurements of remaining polyethylene there was a significant difference between examiners in assessing one of the CT scans, but no difference between scans or trials otherwise.

4.4.2 Comments

A systematic difference for cup 6 due to multiple wear tracts was found. For this cup the CMM data of the polyethylene liner was reexamined searching for the second most worn area but the micrometer measurements could not be repeated, since the polyethylene liner had been sliced for further analyses, and here the micrometer measurement was omitted. The systematic difference between examiners in assessing remaining polyethylene was due to different interpretation of metallic artefacts.

Consequently the method allows for accurate detection of wear at a clinically relevant level. Measurements of remaining polyethylene were slightly less reliable due to metallic artefacts.

5 DISCUSSION

The overall aim of this thesis was to develop and test a new CT method for evaluation of orthopedic implants. The pelvis, acetabular cup, and femoral component head were used as model system.

Studies I and II show that using CT together with volume registration to detect migration, is possible. Even with outmoded CT and computer technique the detection level, in vivo as well as in a model situation, is superior to what can be expected from conventional planar radiology.

The new CT method gives a visual as well as a numerical output. In the visual assessment of migration there are only the errors of volume registration and these errors can at least partially be compensated for by comparing the matching of the bone with that of the prosthesis. This can be used by the examiner in the decision between migration - no migration, and here a further development of the method have been made since these articles were published.

Already in 1996 CT was used to evaluate loosening of the femoral component[38]. Prior to revision surgery of hip prosthesis CT scans of the affected hip and ipsilateral distal femoral epicondyles were made with the leg in internal and external rotation. On axial CT slices the angle between the neck of the femoral component and the a line through the femoral epicondyles were measured, and the difference between external and internal rotation computed. These measurement were then compared with findings at surgery. With this method some, but not all, of the prosthesis that were loose at surgery could be identified as having a larger angular difference between internal and external rotation scan.

There are to date no longitudinal studies on migration using our new CT method. However, in a pilot study an adaptation to it have been tested, making a provocation-CT-examination of the pelvis and hip prosthesis[39]. In this study ten patients were scanned twice with CT, with the affected hip in forced external and internal rotation. Volume registration of the pelvis in the two examinations were made and the resulting volumes examined for implant migration by two examiners. The method was applicable in eight of the ten patients. One patient had a severe tremor, causing image artefacts, and in another patient the hip was ankylotic due to massive ectopic bone formation. Of the remaining eight patients 3 out of 4 cups loose on surgery were seen moving on provocation-CT. 4 out of 4 cups stable on surgery were not moving on provocation-CT.

The provocation-CT-examination is now used clinically at the Karolinska University Hospital in Solna, for evaluation of hip prostheses, both cup and femoral component, where a clinical suspicion of loosening cannot be confirmed on routine planar radiographs.

In Study I, using an old spiral CT scanner, the radiation dose for the scan was only 0.8 mSv. For modern multislice CT scanners the radiation dose increases to approximately 3-5 mSv depending on the protocol used.

Measurement of implant position using a 2D modality is dependent on patient positioning during examination. With a 3D modality malpositioning during examination can (at least to some extent) be compensated for.

It has been shown that the individual flexion angle of the pelvis is relatively constant over time, even before and after a THA operation, but changes between the

supine position, in which most radiographs and CT scans are taken, and functional positions like standing and/or sitting, affecting measurements of implant position, for example cup anteversion[40][34][35]. Also, at THA operation, intraoperative measurements have shown a significant variation of the initial position of the pelvis between patients as well as significant pelvic motion during surgery [22].

Being able to relate measurements of position to the bone rather than to the coordinates of the imaging modality can be used as a first step to a more functional evaluation of implant position.

In Study III a locally developed standard orientation tool was validated and proven to be precise, with only random errors. By using a pelvic standard orientation, measurement of position, wear or migration, can be made relative the bone rather than to the coordinate system of the CT scanner. However, to transfer data obtained in the supine position to, for example, the standing or sitting position, the pelvic orientation needs to be assessed in these positions as well. This can be done by a strictly lateral radiograph [22][34][35] or with a physical device[41].

In Study III it was a CT volume of the pelvis that was placed in a standard orientation, but the standard orientation tool could theoretically be used for any bone, if suitable anatomical landmarks are available.

Study IV presents an easy way to measure both linear wear and the remaining polyethylene three-dimensionally with CT. Using simple spheres fit to the femoral component head and acetabular cup the accuracy of linear wear was 0.6 mm and 1.0 mm respectively for the two examiners. In a follow up study on the same cups[42], a different landmarking pattern for the prosthesis, using 200 evenly spread 3D point landmarks on the 3D isosurface of the femoral component head and another 200 on the outer surface of the cup, was tested and showed an accuracy of 0.6 mm.

A further modification of the software allowing the examiner to “spray” the isosurface of the prosthetic components with point landmarks, making it possible to place fifty to a hundred landmarks/second, has brought the detection level down to 50 micrometer in a test made on a series of model CT scans from Harvard University, Boston. At this point, the metal artefacts still surrounding the implants presently make it difficult to achieve an even better detection level.

However, if the promise of dual energy CT in reducing metal artefacts is met, further improvement might still be made.

Another future possibility is matching a virtual contour of the implant to the same implant in the CT volume, as has already been tried on planar radiographs together with RSA. Data to create a virtual contour of the implant could be attained either by using Computer Aided Design (CAD) data from the manufacturer or, by the use of reverse engineering (RE) techniques to capture implant geometry[10].

6 CONCLUSIONS

These four studies present the basic principles of a new CT method, combining volume registration of CT data for migration detection, and landmarking of the prosthetic components to get a numerical correlate to migration and wear detection. It also offers validation of a locally developed image post processing tool for standard orientation.

Compared to the use of conventional radiographs in clinical routine, migration and wear detection were shown to be improved with this new CT method. For migration in the ideal situation of a model study, the detection level visually, as well as numerically, was below 1 mm. In assessing wear of the acetabular cup the simple method tested in Study IV had a detection level for linear penetration depth in 3D of approximately 1 mm.

The locally developed tool for reorienting the CT volume in postprocessing was shown to be accurate and precise, enabling measurements relative to the bone or other chosen structure in the volume and minimizing the dependency on patient positioning.

7 ACKNOWLEDGEMENTS

This thesis is part of a multi-disciplinary development project for a non-invasive method for accurate routine evaluation of orthopedic implants, based on CT. It really has required a team effort and I very much would like to thank everyone on the team.

Peter Aspelin, my head supervisor, for being able to see both the greater perspective and the more practical points.

Marilyn Noz, Gerald Q Maguire Jr and Michael P Zeleznik, for providing the image registration, standard orientation, and wear detection software, together with updates and new applications when needed. Marilyn Noz, as co supervisor, for continuous help whenever needed with almost every aspect of the project.

Lars Weidenhielm, as co supervisor, for adding the viewpoint of the orthopedic surgeon, and together with André Stark being excellent links between radiology and orthopaedics.

Staffan Troell, co supervisor, for encouragement and support and for sharing his long experience of radiology.

Veli Söderlund, for practical advice on radiology and taking over as co supervisor after Staffan Troell's retirement.

Henrik Olivecrona, for great teamwork all through this project.

Mats Beckman and Joakim Crafoord, for sharing their knowledge in CT.

My wonderful colleges and the helpful staff at ADR – radiology department of KS Solna, who made the sometimes hard work of radiology enjoyable.

Lars Svensson, for his invaluable help with the mathematical solutions.

Torbjörn Jonson, for programming the mathematical module.

Anneli Jedenmalm, for adding the competence of KTH.

Bengt Lind and the people at the Department for Medical Radiation Physics KI, for allowing time on their computer and providing an inspiring place to work.

The patients, for kindly participating in the studies

Svensk Reumakirurgisk Förening, for financial support during my thesis writing.

And finally, Helena Forssell for the competent help during the whole process of thesis writing.

8 REFERENCES

- [1] W. Hendee and R. Ritenour, *Medical Imaging Physics*, fourth edition, 2002; Wiley-Liss, Inc . (NY) ISBN_10-0471382264.
- [2] H. Malchau, P. Herberts, and L. Ahnfelt, Prognosis of total hip replacement in Sweden. Follow-up of 92675 operations performed 1978-1990, *Acta Orthop Scand*. 1993; 64:497-506.
- [3] L.S. Lothmander, L.B. Engesaeter, P. Herberts, T. Ingvarsson, U. Lucht, and T. Poulakka, Standardized incidence rates of total hip replacement for primary osteoarthritis in the 5 Nordic countries: similarities and differences *Acta Orthop*. 2006; 77:733-740.
- [4] M. Krismer, R. Bauer, J. Tschupik, and P. Mayrhofer, EBRA: a method to measure migration of acetabular components. *J Biomech*. 1995; 28: 1225-1236.
- [5] N.J. Phillips, I. Stockley, and J.M. Wilkinson, Direct plain radiographs methods versus EBRA-Digital for measuring implant migration after total hip arthroplasty *J.f Arthroplasty* 2002; 17:917-925.
- [6] C.J. Sutherland and S.J. Bresina, Measurements of acetabular cup migration, using two-dimensional radiography. *J Arthroplasty (Suppl)* 1992; 7:377-379.
- [7] H. Malchau, J. Kärrholm, Y.X. Wang, and P. Herberts, Accuracy of migration analysis in hip arthroplasty. Digitized and conventional radiography, compared to radiostereometry in 51 patients. *Acta Orthop Scand* 1995; 66:418-424.
- [8] J.M. Wilkinson, A.J. Hamer, R.A. Elson, I. Stockley, and R. Eastell, Precision of EBRA-Digital Software for Monitoring Implant Migration After Total Hip Arthroplasty. *J Arthroplasty* 2002; 17:910-916.
- [9] N. Börlin, S.M. Röhrli, and C.R. Bragdon, RSA wear measurements with or without markers in total hip arthroplasty. *J Biomech* 2006; 39:1641-1650.
- [10] F. Seehaus, J. Emmerich, B.L. Kaptein, H. Windhage, and C. Hurschler, Experimental analysis of Model-Based Roentgen Stereophotogrammetric Analysis (MBRSA) on four typical prosthesis components *J. Biomech. Eng.* 2009; 131:041004.
- [11] J. Kärrholm, P. Herberts, P. Hultmark, H. Malchau, B. Nivbrant and J. Thanner, Radiostereometry of hip prostheses. Review of methodology and clinical results. *Clin Orthop* 1997; 344: 94-110.
- [12] J.M. Wilkinson, A.J. Hamer, R.A. Elson, I. Stockley, and R. Eastell, Precision of EBRA-Digital Software for Monitoring Implant Migration After Total Hip Arthroplasty. *J Arthroplasty* 2002; 17:910-916.
- [13] T. Ilchmann, Radiographic assessment of cup migration and wear after hip replacement. *Acta Orthop. Scand. Suppl.* 1997; 276:1-26.
- [14] J. Livermore, D. Ilstrup, and B. Morrey, Effect on Femoral Head Size on Wear of the Polyethylene Acetabular Component. *J Bone Joint Surg* 1990; 72:518-528.

- [15] J. Martell, and S. Berdia, Determination of polyethylene wear in total hip replacement with use of digital radiographs. *J Bone Joint Surg* 1997;79-A:1635-1641.
- [16] A. Hui, R. McCalden, J. Martell, S. MacDonald, R. Bourne, and C. Rorabeck,. Validation of two- and three-dimensional radiographic techniques for measuring polyethylene wear after total hip arthroplasty. *J Bone Joint Surg* 2003; 85-A:505-511.
- [17] P. Devane, R. Bourne, C. Rorabeck, R. Haradie, and G. Horne, Measurements of polyethylene wear in metal backed cups. I. Three-dimensional technique. *Clin Orthop Relat Res* 1995; 319:303-316.
- [18] P. Devane, R. Bourne, C. Rorabeck, S. MacDonald, and E. Robinson, Measurements of polyethylene wear in metal backed cups. II. Clinical application. *Clin Orthop Relat Res.* 1995; 319:317-326.
- [19] D.W. Murray, The definition and measurement of acetabular orientation. *J Bone Joint Surg* 1993; 75-B:228-32.
- [20] L. Yao, J. Yao, and R. Gold, Measurement of Acetabular version on axiolateral radiograph. *Clin Orthop Relat Res* 1995; 316: 106-111.
- [21] S. Mian, G. Thuchly, and F. Pflum, Computer tomography measurements of acetabular cup anteversion and retroversion in total hip arthroplasty. *Clin Orthop Relat Res.* 1992; 276:206-209.
- [22] A.M. DiGiola, B. Jaramaz, M. Blackwell, D. Simon, F. Morgan, J. Moody, C. Nikou, B. Colgan, C. Aston, R. Labarca, E. Kieschell, and T. Kanade, The Otto Aufranc award: Image guided navigation system to measure intraoperatively acetabular implant alignment. *Clin Orthop* 1998; 335:8-22.
- [23] T. Leenders, D. Vandeveld, G. Mahieu, and R. Nuyts, Reduction in variability of acetabular cup abduction using computer assisted surgery: a prospective and randomized study. *Computer Aided Surgery* 2002; 7:99-106.
- [24] H. Olivecrona, L. Weidenhielm, L. Olivecrona, M.E. Noz, G.Q. Maguire Jr, M.P. Zeleznik, L. Svensson, and T. Jonson, Spatial component position in Total Hip Arthroplasty. Accuracy and repeatability with a new CT method. *Acta Radiol* 2003; 44:84-91.
- [25] H. Olivecrona, L. Olivecrona, L. Weidenhielm, A. Stark, M.E. Noz, G.Q. Maguire Jr, M.P. Zeleznik, L. Svensson, and T. Jonson, Stability of Acetabular axis after Total Hip Arthroplasty. Repeatability using CT and a semiautomated program for volume fusion. *Acta Radiol.* 2003; 44:653-661.
- [26] H. Olivecrona, L. Weidenhielm, L. Olivecrona, M.O. Beckman, A. Stark, M.E. Noz, G.Q. Maguire Jr, M.P. Zeleznik, L. Svensson, and T. Jonson, A new CT method for measuring cup orientation after total hip arthroplasty. A study of 10 patients. *Acta Orthop Scand* 2004; 75:252-260.
- [27] M.E. Noz, and G.Q. Maguire Jr., QSH: A Minimal but Highly Portable Image Display and Handling Toolkit. *Comp Meth Progr Biomed* 1988; 27:229-240.
- [28] M.E. Noz, G.Q. Maguire Jr, M.P. Zeleznik, E.L. Kramer, F. Mahmoud, and J.A. Crafoord, Versatile Functional-Anatomical Image Fusion Method for Volume Data Sets *J Medical Systems* 2001; 5:297-307.

- [29] M.E. Noz, H. Rusinek, J. Jaeger, E.L. Kramer, J.J. Sanger, and G. Smith, Graphics Applied to Medical Image Registration. *IEEE Comput Graph Appl* 1991; 11:20-29.
- [30] R.J.T. Gorniak, E.L. Kramer, G.Q. Maguire Jr, M.E. Noz, C.J. Schettino, and M.P. Zeleznik, Evaluation of a Semi-automatic 3D Fusion Technique Applied to Molecular Imaging and MRI Brain/Frame Volume Data Sets. *J. Med Syst* 2003; 27:141-156.
- [31] J. Crafoord, F. Mahomoud, E.L. Kramer, G.Q. Maguire Jr, M.E. Noz, and M.P. Zeleznik, Comparison of Two landmark Based Image Registration Methods for Use With a Body Atlas. *Physica Medica*. 2000; 2:75-82.
- [32] A. Birnbaum, M.E. Noz, J. Chapnick, J.J. Sanger, A. Megibow, G.Q. Maguire Jr, J.C. Weinreb, E.M. Kaminer, and E.L. Kramer, Hepatic Hemangiomas: Diagnosis with Fusion of MR, CT, and Tc-99m-labeled Red Blood Cell SPECT Images. *Radiology* 1991; 181:469-474.
- [33] B. McKibbin, Anatomical factors in the stability of the hip joint in the newborn. *J Bone Joint Surg Br*. 1970; 52:148-59.
- [34] A.M. DiGiola, M.A. Hafez, B. Jaramaz, T.J. Levison, J.E. Moody, Functional Pelvic Orientation Measured from Lateral Standing and Sitting Radiographs *Clin Orthop Relat Res*. 2006; 453: 272-276.
- [35] R Philippot, J Wegrzyn, F Farizon, M.H.Fessy. Pelvic balance in sagittal and Lewinnek reference planes in the standing supine and sitting positions. *Orthopaedics & Traumatology: Surgery & Research*. 2009; 95:70-76.
- [36] ISO, Accuracy (Trueness and Precision) of Measurement Methods and Results - Part 1: General Principles and Definitions International Standard ISO 5725-1: Dec 15, 1994.
- [37] J. Ranstam, L. Ryd, I. Önsten, Accurate accuracy assessment. *Acta Orthop Scand* 2000; 71:106-108.
- [38] R.W. Reinus, K.C. Merkel, J.J. Gilden, and K.L. Berger, Evaluation of Femoral Prosthetic Loosening Using CT Imaging. *AJR* 1996; 166:1439-142.
- [39] H. Olivecrona, L. Olivecrona, L. Weidenhielm, M.E. Noz, J. Kardos, G.Q. Maguire Jr, M.P. Zeleznik, and P. Aspelin, A new technique for diagnosis of acetabular cup loosening using computed tomography. *Acta Orthop*. 2008; 79:346-353.
- [40] T.A. Eddine, H. Migaud, C. Chantelot, A. Cotten, C. Fontaine, and A. Duquenooy, Variations of pelvic anteversion in the lying and standing positions: analysis of 24 control subjects and implications for CT measurement of position of a prosthetic cup. *Surg Radiol Anat* 2001; 23:105-110.
- [41] S. Anda, S. Svenningsen, T. Grøntvedt, and P. Benum, Pelvic inclination and spatial orientation of the acetabulum. *Acta Radiol*. 1990; 31:389-394.
- [42] A. Jedenmalm, M.E. Noz, H. Olivecrona, L. Olivecrona, A. Stark, A new approach for assessment of wear in metalbacked acetabular cups using computed tomography. *Acta Orthop* 2008; 79:218-224.