

From the Retinal and Oncology Service at S.t Erik's Eye Hospital and Karolinska Institutet
and the Department of Oncology and Pathology, Division of Cellular and Molecular Tumor
Pathology, Karolinska Hospital and Karolinska Institutet, Stockholm, Sweden

UVEAL MELANOMA: CYTOGENETICS, MOLECULAR BIOLOGY AND TUMOR IMMUNOLOGY

Charlotta All-Ericsson



Stockholm 2002

All previously published papers were reproduced with permission from the publisher.

Published and printed by Karolinska University Press
Box 200, SE-171 77 Stockholm, Sweden
© Charlotta All-Ericsson, 2002
ISBN91-7349-278-7

To Carl-Fredrik and Christoffer

ABSTRACT

Uveal melanoma is the most common primary intraocular malignancy. The metastatic spread is hematogenous and exclusively to the liver. Although eye-sparing treatments are used more frequently the tumor-related mortality in uveal melanoma is still 30-50%. Only 2% of the patients have detectable metastases at the time of diagnosis. The aim of this study was to test various prognostic markers and possibly new treatment modalities.

Chromosomal aberrations were studied on 35 paraffin-embedded tumor specimens with comparative genomic hybridization (CGH) technique. 29 out of 35 tumors showed copy number changes. The most common losses were on chromosome 3, 6q, and 1p and the most common gains on chromosome 8q, 6p and 1q. The mean number of DNA copy number changes was significantly higher in the metastasizing tumors and metastases.

The expression of human leukocyte antigen (HLA) class I, beta-2-microglobulin and HLA class II were studied with immunohistochemistry (IHC) on 65 tumor samples. In all three groups high expression was correlated to an adverse clinical outcome.

The insulin-like growth factor-1 receptor (IGF-1R) has been implicated as an important factor for tumor progression in several different tumors. We could show by both IHC and Western blotting (WB) that IGF-1R is expressed in uveal melanoma. Furthermore we were able to induce cell growth arrest and cell death by using tunicamycin and lovastatin, which inhibit the N-linked glycosylation, and α IR-3 which blocks the binding domain of IGF-1R.

Previous studies have indicated that the proto-oncogene c-kit is important in tumor progression. We found when using IHC that 84 out of 134 (64%) tumors expressed c-kit. This result could be confirmed by WB where 6 out of 8 samples expressed c-kit. To study the anti-proliferative effects of the tyrosine kinase inhibitor STI571 we treated four uveal melanoma and two skin melanoma cell lines. Cell proliferation was completely inhibited after 48h by 0.1-1 μ M STI571 in the uveal melanoma cell lines but not in the skin melanoma cell lines.

In conclusion, this study suggests that chromosomal aberrations on chromosome 1, 3, 6 and 8, and expression of HLA may be used as prognostic markers and that the IGF-1R and c-kit may in the future be used as therapeutic targets.

KEY WORDS: Uveal melanoma, prognostic markers, treatment, CGH, chromosomal aberrations, HLA, IHC, Western blotting, IGF-1R, c-kit, STI571

LIST OF PAPERS

This thesis is based on the following papers, which will be referred to by their Roman numerals:

- I. Aalto Y, Ericsson C, Seregard S, Larsson O and Knuutila S. Concomitant loss of chromosome 3 and whole arm losses and gains of chromosome 1, 6 or 8 in metastasizing primary uveal melanoma. *Invest Ophthal Vis Sci*, 2001; 42: 313-317.

- II. Ericsson C, Seregard S, Bartolazzi A, Levitskaya E, Ferrone S, Kiessling R and Larsson O. Association of HLA class I and class II antigen expression in primary uveal melanoma lesions with increased mortality in metastatic disease. *Invest Ophthal Vis Sci*, 2001; 42: 2153-6.

- III. All-Ericsson C, Girnita L, Seregard S, Bartolazzi A, Jager M and Larsson O. Insulin-like growth factor-1 receptor (IGF-1R) in uveal melanoma: a predictor for metastatic disease and a potential therapeutic target. *Invest Ophthal Vis Sci* 2002; 43: 1-8.

- IV. All-Ericsson C, Girnita L, Brodin B, Seregard S, Östman A and Larsson O. Inhibition of proto-oncogene c-kit: a potential therapeutic target in metastasizing uveal melanoma (manuscript)

All papers are reprinted with permission from the Association for Research in Vision and Ophthalmology.

CONTENTS

Abbreviations	1
Acknowledgements	2
Introduction	4
Anatomy, history and treatment	4
Predisposing lesions	6
Prognosis	7
Prognostic factors.....	7
Tumor location	7
Extrascleral extension.....	7
Tumor size.....	7
Cell type	8
Proliferative activity	9
Vascular patterns	9
Immunology and eye.....	9
Chromosomal aberrations.....	11
Growth factors.....	11
Aims of the study	15
Material and methods	16
Clinical material	16
Chemicals.....	16
Cells	16
Immunohistochemistry	16
Cell culture	17
Assay of cell growth and survival	17
Isolation of cell membranes.....	17
Determination of protein content.....	17
Cell viability assay	17
Immunoprecipitation	18
Sodium dodecyl sulphate polyacrylamide gel electrophoresis (SDS-PAGE).....	18
Western blotting	18
Comparative genome hybridization (CGH).....	18
Polymerase chain reaction (PCR) and sequencing	19
Statistical evaluation	19
Results	20
Paper I.....	20
Paper II.....	20
Paper III.....	21
Paper IV	21
Discussion	22
References	26

ABBREVIATIONS

CGH	Comparative genome hybridization
CML	Chronic myeloid leukemia
CTL	Cytotoxic T lymphocyte
EGFR	Epithelial growth factor receptor
ER	Endoplasmatic reticulum
GIST	Gastrointestinal stromal tumors
HLA	Human leukocyte antigen
HPF	High power field
IGFBP	Insulin growth factor binding protein
IGF-1R	Insulin-like growth factor-1 receptor
IHC	Immunohistochemistry
IRS	Insulin receptor substrate
MAPK	Mitogen-activated protein kinase
MHC	Major histocompatibility complex
MLN	Mean of largest nucleoli
PAS	Periodic acid-Schiff
PCR	Polymerase chain reaction
PDGFR	Platelet derived growth factor receptor
PI3K	Phosphatidylinositol-3 kinase
PKB/Akt	Protein kinase B
SCF	Stem cell factor
SDNA	Standard deviation of the nucleolar area
SDS-PAGE	Sodium dodecyl sulphate polyacrylamide gel electrophoresis
TAA	Tumor associated antigen
TM	Tunicamycin
VEGFR	Vascular endothelial growth factor receptor
WB	Western blotting

ACKNOWLEDGEMENTS

I want to thank everyone who has in different ways helped me during the course of this thesis

Stefan Seregard, my tutor, for introducing me to the scientific world of uveal melanoma, for his great stylistic, statistical and executive skills but above all for his great encouragement, warmth and generosity.

Olle Larsson, my tutor, for generously letting me share the lab resources, for his great integrity and vast scientific knowledge, for enthusiastically receiving my new results, supplementing these with interesting new ideas.

Rolf Kiessling, who helped me in every way almost like a tutor, for his great scientific skill, inspiring guidance and never failing interest.

Leonard Girnita, my great support in the lab, for his patience in teaching me new lab techniques, even if he had taught me the same thing several times before.

Eva Dafgård-Kopp, my friend and colleague, who persuaded Stefan and Olle to let me participate in this project.

Gunnar Lennerstrand, and *Bo Philipson* for their kind support and encouragement

Bertha Brodin, for sharing with me all her knowledge concerning PCR and primers

Sakari Knuutila, *Armando Bartolazzi*, *Elena Levitskaya*, *Soldano Ferrone*, *Martine Jager*, *Arne Östman* for stimulating collaborations

Ada Girnita, *Maria Törnqvist*, *Yuntao Xie*, *Gunnar Nilsson*, for answering all my questions and helping me out when time was short.

Margareta Rodensjö, for all the help and patience concerning the immunohistochemical stainings

Berith Spångberg, *Margareta Oskarsson*, *Carina Zahn*, *Kristi Oscar*, *Anki Frecot*, *Ylva Lagerquist*, *Birgitta Grundstroem* and *Maud Leindahl* for always helping me with a smile even when I asked for help “in the last minute”

Ulla-Britt Schützler-Pettersson and *Britt Marie Karlheden* for valuable help and advice.

Gabor Koranyi, for your “temporary” help when my half-term seminar was lost in cyber space.

Andreas Mårtensson, *Ingrid Ludwigs* and *Fredrik Ellwén* for all the instant, valuable computer help

Lennart, for sharing his surgical knowledge and for all encouragement and friendship.

Erik, for encouraging me all the way through medical school and for always giving me sound advices during the work with this thesis.

Agnes, for all the time you spent listening to me rehearsing my first presentation and for the help when the first ALF application felt like a mountain to climb.

Anna, for long nice encouraging telephone calls, *Irma*, for friendship and valuable advices concerning writing the summary, *Eva*, for endless discussions over a cup of tea, *Frank*, a friend to turn to when everything sometimes felt hopeless, *Anne*, for giving me never ending advices in “life-wisdom”, *Anna*, my mate in the same “house-maintenance” boat, *Annika*, for introducing me to “night-club life”, *Anna & Erik* for encouragement and several nice dinners, *Ingela & Bette*, my supporting neighbours.

To my family for love and support.

The work was partly supported by grants from *Cancerföreningen i Stockholm/ Konung Gustav V:s Jubileumsfond, Cancerfonden, Stiftelsen Kronprinsessan Margaretas Arbetsnämnd för Synskadade, Stiftelsen Synfrämjandets Forskningsfond, Karin Sandqvists stiftelse, Karolinska institutet, Carmen och Bertil Regnérs Stiftelse för forskning inom Området Ögonsjukdomar.*

INTRODUCTION

Anatomy, history and treatment

Uveal melanoma is a rare malignancy that threatens both sight and life. Malignancies are not merely a disorder of individual cells. Transformed cells grow into tumor masses, and they invade and metastasize through surrounding tissues. Knowledge of the molecular basis for these complex processes is important for understanding the natural history of malignant disease.

The uveal tract is the pigmented vascular coat of the eye consisting of the iris, ciliary body and choroids. It is composed of many blood vessels, a variable number of melanocytes, supporting connective tissue and nerves. (Fig 1).

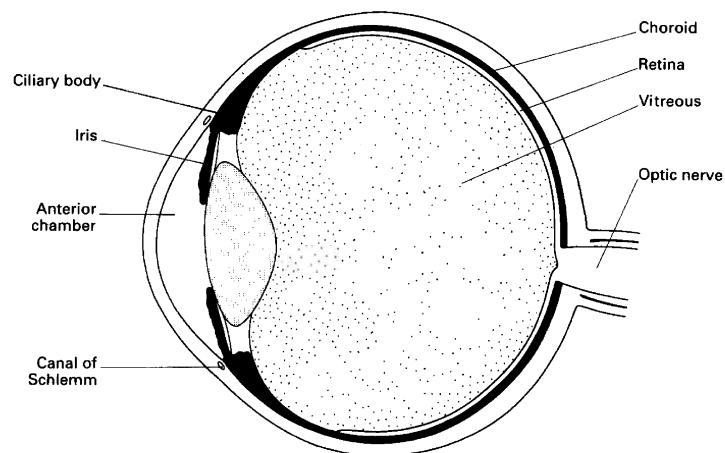


Fig. 1. The uveal tract is composed of the iris, ciliary body and the choroid (black).

Uveal melanoma has had a variety of descriptive names: melanosarcoma for tumors of spindle cell type; melanocarcinoma for tumors of epitheloid cell type; leucosarcoma for amelanotic varieties; angiosarcoma for highly vascular tumors; and giant cell sarcoma for anaplastic tumors containing giant cells, often multinucleated. In the last decades the term uveal malignant melanoma has been used and is recommended by the World Health Organization.

Melanocytes are present in the uvea of the eye and in the retinal pigment layer having migrated as melanoblasts from the neural crest. Further locations of neural crest derived melanocytes are in the inner ear, the skin, the hair follicles and the leptomeninges. Uveal melanocytes are involved in the pathogenesis of a variety of eye diseases, the most important of which is malignant melanoma the most common primary malignant intraocular tumor in adults, with an annual incidence of approximately six cases per million per year in Caucasians (Strickland et al. 1981) (Osterlind 1987) (Egan et al. 1988). The incidence in whites is eight times that in blacks and three times greater risk than Asians (Egan et al. 1988). This could point to the causal role of ultraviolet (UV) light in tumorigenesis (Holly et al. 1990) (Sahel et al. 1997). In contrast to these findings, however, is the fact that the incidence of uveal melanoma compared with cutaneous melanoma has not increased during the last 40 years (Bergman et al.) (Dolin et al. 1994) and a higher incidence is not found in the most light-exposed areas of the eye (Schwartz et al. 1997). Therefore the role of UV exposure in the causation of uveal melanoma is controversial. Although uveal and cutaneous melanoma are from similar embryological origin, they differ in biological behavior. Choroidal and ciliary body melanomas metastasize hematogenously and preferentially to the liver in 95%, (Callender 1931) (Einhorn et al. 1974) (Raivio 1977) (Char 1978) (Zimmerman et al. 1983) (Albert et al. 1992). In comparison with skin melanoma which is reported to metastasize to the liver in 4 and 13 %, respectively. (Das Gupta et al. 1964) (Magnus 1977). The liver frequently is the sole site of metastasis in uveal melanoma, (Jensen 1970) while cutaneous melanoma spreads preferentially to adjacent lymph nodes and single organ metastasis is extremely uncommon (Magnus 1977) (Stehlin et al. 1967). There are no demonstrated lymphatics within the uveal tract or in the posterior orbit, although it has been reported lymphatic spread through lymphatics in the conjunctiva from uveal melanoma (Dithmar et al. 2000). This predominance of liver involvement in uveal melanoma is in clear contrast to cutaneous melanoma, where the incidence of liver metastasis is lower, usually 15-20 % (Meyers et al. 1998). Other sites of metastasis include the lungs (30-35%), bones (20-25%), skin (15-20%) and lymph nodes (10-15%), as well as the pancreas, heart, spleen, adrenal glands, gastrointestinal tract, kidneys, ovaries and thyroid. These metastases generally occur in association with liver metastases (Cantore et al. 1994) (Sahel et al. 1997). Brain metastases, commonly observed in cutaneous melanoma, are rarely observed in uveal melanoma.

In the past all patients with uveal melanoma underwent enucleation. Fuchs claimed as early as 1882 that patients with uveal sarcoma (melanoma) almost inevitably died from their disease and that enucleation was the treatment of choice (Fuchs 1882). Today alternative treatment modalities, including radiotherapy, local resection and transpupillary thermotherapy have made it possible to retain eyes. Radiotherapy was first used in 1930 by Moore (Moore 1930). Later the technique was further developed by Stallard who introduced the use of cobalt-60 episcleral plaques (Stallard 1966). Since 1964 the ruthenium-106 episcleral plaques have become widely used, introduced first by Lommatzsch. Today ruthenium-106 as well as iodine-125, palladium-103 and iridium-192 episcleral plaques are used (Packer et al. 1980) (Garretson et al. 1987) (Packer 1987) (Finger et al. 1994) (De Potter et al. 1994). Charged-particle irradiation, e.g. proton beam or helium ion radiotherapy, constitutes an alternative treatment modality, however, is it limited by the availability of appropriate therapeutic facilities (Char et al. 1980) (Gragoudas et al. 1980). During a period photocoagulation was used as a therapy but it was associated with frequent tumor regrowth (Barr et al. 1983). Local resection of tumors in the anterior part of uvea has been practiced since the early 1900s (Zirm 1911) (Schubert 1925). Several investigators have during the last decades further developed the technique (Foulds 1973) (Peyman et al. 1984) (Damato et al. 1996) (Char et al. 2001). Since 1995 a new treatment modality, transpupillary thermotherapy, has made it possible to treat smaller lesions with less complications and may be used as adjuvant to brachytherapy (Oosterhuis et al. 1995) (Oosterhuis et al. 1998) (Shields et al. 1998) (Seregard et al. 2001) (Shields et al. 2002).

Predisposing lesions

Ocular melanocytosis (Gonder et al. 1982) (Gonder et al. 1981) and nevi (Naumann et al. 1966) (Gass 1977) (Yanhoff et al. 1967) are two lesions that predispose to the development of uveal malignant melanoma. In some cases of ocular melanocytosis the hyperpigmentation includes periocular skin and is then referred to as oculodermal melanocytosis or naevus of Ota. Uveal nevi progress to malignant melanoma less frequently than does ocular melanocytosis. Based on the high prevalence of uveal nevi (5% of eyes) and the low incidence of uveal melanoma (7 per 1,000,000 per year), it can be estimated that the rate of transformation of nevi to malignant melanoma is, at most, 1 per 10,000 to 15,000 per year. The difficulty with early detection of choroidal melanoma relates to its clinical similarity to benign choroidal nevus. Shields et al have introduced the mnemonic TFSOM indicating To Find Small Ocular Melanoma, to better help clinicians to identify small choroidal melanomas. The letters in the mnemonic represent, Thickness >2mm, subretinal Fluid, Symptoms, Orange pigment and Margin touching optic disc. Tumors that display one factor have a 38% chance for growth and those with two or more factors show growth in over 50% of cases at 5 years (Shields et al. 2002).

Prognosis

Despite high accuracy of diagnosis the mortality due to uveal melanoma has remained unchanged (Shields et al. 1980) (Shields et al. 1992) (Strickland et al. 1981). The overall prognosis is significantly worse than that of cutaneous melanoma, with the 5 year and 15 year survival rates being 72% and 53% respectively (Diener-West et al. 1992) (Gamel et al. 1993). Approximately 40% of patients with posterior uveal melanoma develop metastatic melanoma to the liver within 10 years after initial diagnosis and treatment (Shields et al. 1991). It is well known that the incidence of metastases at the time of diagnosis is very low, only 2-3%, using conventional methods as liver enzymes and liver scans (Pach et al. 1986) (Wagoner et al. 1982). This fact has made some authors suggest that removal of the primary tumor by enucleation may actually promote the dissemination of malignant cells (Zimmerman et al. 1978). In order to lower melanoma-related mortality, it is essential to prevent metastatic disease. This calls for early detection and for the development of reliable prognostic factors. The median survival after clinical diagnosis of hepatic metastasis is extremely poor. The median survival time after diagnosed metastatic spread is less than seven months (Rajpal et al. 1983) (Seddon et al. 1983) (Kath et al. 1993) it is assumed that tumor dissemination occurs prior to primary tumor therapy. The metastatic tumor cells are considered to be "dormant" for a period as long as 40 years after the initial diagnosis (Coupland et al. 1996).

Prognostic factors

Tumor location

Uveal melanoma can arise in the iris, the ciliary body or the choroid. Iris melanomas (3% of cases) are relatively small when diagnosed and treated (Jensen 1970) (Shields et al. 2001). Iris melanoma has the lowest 5-year mortality rate with 2-3 % (Geisse et al. 1985). Ciliary body melanoma has a worse prognosis compared to the others (Seddon et al. 1983). Although ciliary body melanomas tend to be larger at the time of diagnosis compared with choroidal melanoma it has been established that the poor prognosis is independent of tumor size and cell type (Seddon et al. 1983) (McLean et al. 1977).

Extrascleral extension

The presence of extrascleral extension is observed in about 8% of enucleated eyes (1998). In such cases the 10-year mortality is doubled to about 75% compared with cases with no extrascleral extension (Seddon et al. 1983)

Tumor size

Various measurements have been used to represent the tumor size. In a meta-analysis of eight published reports on mortality rates of uveal melanoma following enucleation, uveal melanomas were classified into three groups based on diameter and height (Diener-West et al. 1992). The study confirmed that tumor size at the time of enucleation is a major prognostic factor.

Category	Factor	Outcome	Result	Reference	
Tumor location	Iris	10 year mortality	6%	Shields et al, 2000	
	Ciliary	5 year mortality	53%	Seddon et al, 1983	
Extrascleral extension		5 year mortality	22%	Gunduz et al, 1999	
	Choroidal	5 year mortality	14%	Seddon et al, 1983	
	Absent	10 year mortality	37%	Seddon et al, 1983	
	Present	10 year mortality	75%	Seddon et al, 1983	
Size	Small	5 year mortality	16%	Diener-West et al, 1992	
		5 year mortality	3%	Shields et al, 1995	
		5 year mortality	1%	COMS, 1997	
	Medium	5 year mortality	32%	Diener-West et al, 1992	
	Large	5 year mortality	53%	Diener-West et al, 1992	
Cell type	Spindle	15 year mortality	20%	McLean et al, 1982	
	Mixed	15 year mortality	60%	McLean et al, 1982	
	Epitheloid	15 year mortality	75%	Shammas et al, 1977	
Proliferative activity	Mitotic activity	Low	6 year mortality	15%	McLean et al, 1977
		Medium	6 year mortality	43%	McLean et al, 1977
		High	6 year mortality	56%	McLean et al, 1977
PC-10		Low	10 year mortality*	16%	Seregard et al, 1996
		High	10 year mortality*	60%	Seregard et al, 1996
Vascular patterns	Absent	10 year mortality	10%	Folberg et al, 1993	
	Present	10 year mortality	50%	Folberg et al, 1993	

* Modified after cumulative 10-year survival proportion

Table Clinical and histopathological prognostic factors in uveal melanoma. Modified after Singh et al, 2001

Cell type

In 1931 Callender proposed a classification system for uveal melanoma based on cell type (Callender 1931). McLean subsequently modified the system (McLean et al. 1983). Uveal malignant melanomas are divided into three main cytological types: spindle, mixed and epitheloid. Spindle cell tumors have a better prognosis than either mixed or epitheloid cell uveal melanomas (McLean et al. 1994). Since characterization of cell type is subjective, morphometric criteria have been proposed. The standard deviation of the nucleolar area (SDNA) is prognostically significant (Seddon et al. 1987). However, measurement of SDNA requires specialized equipment and is time consuming. The measurement of the mean of the diameters of the 10 largest nucleoli, mean of largest nucleoli (MLN) is a more simple method and provides similar prognostic information (Gamel et al. 1992).

Proliferative activity

Proliferative activity as measured by the number of mitoses seen per high power field (HPF) or by looking at the immunoexpression of PC-10 appears to be of prognostic value in some studies (McLean et al. 1977) (Seregard et al. 1996). In a study of 217 uveal melanomas McLean et al observed that tumor mitotic activity correlated with mortality. Tumors with low mitotic activity (0-1 HPF) had good prognosis, with a 6-year mortality of 15% compared with 56% in tumors with high mitotic activity (9-48 HPF) (McLean et al. 1977). Seregard et al showed in their study that the PC-10 count could be of prognostic value in uveal melanoma when adjusting for the effect of MLN and vascular patterns (Seregard et al. 1998).

Vascular patterns

Studies on pathology slides have suggested that the presence of microcirculation architecture (vascular patterns) is a strong prognostic factor for metastatic death (Folberg et al. 1992) (Rummelt et al. 1995). Histopathology slides from paraffin embedded blocks are stained with modified periodic acid-Schiff reagent to evaluate the vascular patterns. Nine types of microcirculation architecture have been described, including; incorporation of normal vessels into the tumor, avascular zones, PAS-positive parallel vascular channels without and with cross linking, arcs with and without branching, loops, networks (defined as a focus of at least three back-to-back loops) and silent pattern (avascularity) (Folberg et al. 1993). Folberg et al reported in multivariate Cox models that loops and networks were independently associated with mortality from metastatic melanoma (Folberg et al. 1993). The association between vascular patterns and death from metastatic melanoma have also been found by other investigators (Sakamoto et al. 1996) (Makitie et al. 1999). Recently, it was reported that not just only loops and networks are associated with an adverse prognosis; also other angiographic patterns may reflect an aggressive tumor behavior (Folberg et al. 2001).

Immunology and eye

The unique immunological characteristics of the anterior chamber of the eye have been recognized for over a century (Niederhorn 1990) (Streilein 1995). Histoincompatible tissue grafts survive for extended periods within the anterior chamber of the eye, yet are promptly rejected when transplanted to extraocular sites. Although it was previously believed that immunological privilege was restricted to the anterior chamber, later evidence clearly indicates that the posterior compartments of the eye also possess immunological properties similar to the anterior chamber (Jiang et al. 1993) (Jiang et al. 1994).

CD8+ T-cells play a major role in the antitumor associated antigen immune response (Ferrone et al. 1995). However, abnormalities in the major histocompatibility complex (MHC) class I antigens are frequently found in human malignant cells, which has set the focus on the control of tumor growth by tumor associated antigen (TAA)- specific CD4+ cells (Rees et al. 1999). The HLA class I molecules (HLA-A, B and C) assemble in the endoplasmic reticulum (ER) and the HLA class I heavy chain and the β_2 -microglobulin (β_2m) are then transported via the trans-Golgi apparatus. The resulting trimolecular HLA class I complex is then expressed on the cell surface for presentation to CD8+ cytotoxic T lymphocytes (CTL) (Fig.2)

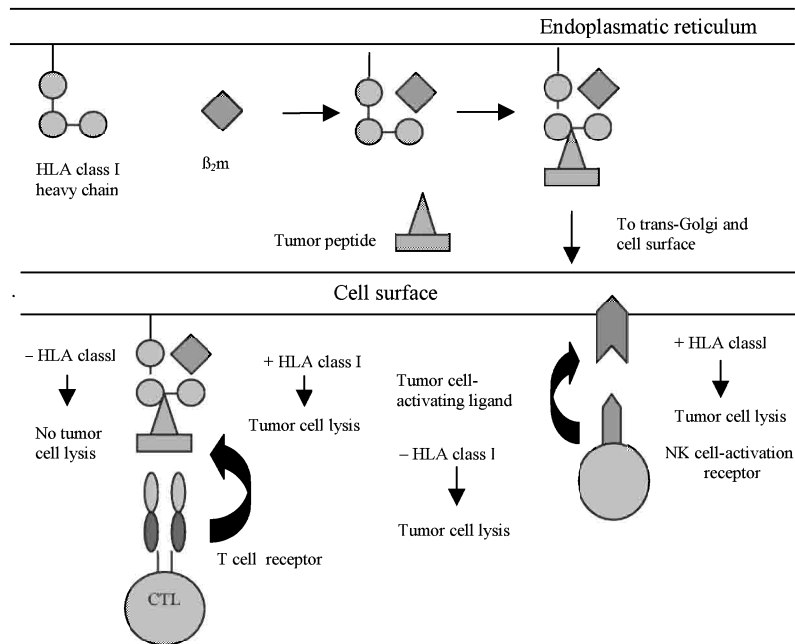


Fig. 2. Human leukocyte antigen (HLA) class I processing and presentation. The tumor peptides are translocated to the endoplasmic reticulum (ER) where they are loaded onto HLA class I molecules. HLA class I heavy chain- β 2-microglobulin-tumor peptide complex exit the ER and travel to the cell surface. Tumor peptides are presented to T cell receptors on cytotoxic T lymphocytes (CTLs). HLA class I downregulation can result in lack of tumor cell recognition by CTLs. Tumor cells control natural killer (NK) cell recognition through the interaction of HLA class I antigens. HLA class I downregulation eliminates a negative signal and results in the activation of cytotoxicity by NK cells.

HLA class II molecules (HLA-DR, DP and DQ) are also assembled in the ER and transported to the cell surface to present peptides derived either from self or foreign antigens to CD4⁺ T cells. Natural killer (NK) cells are a subset of lymphocytes found in blood and lymphoid tissues and are believed to play an important role in the immune surveillance of virus infections and neoplasms. NK cells selectively lyse tumor cells that do not express one or more HLA class I alleles. It is now becoming clear that when the immune system encounters a new antigen, e.g. a tumor antigen, the outcome may well be tolerance rather than activation (Jenkins et al. 1987). This may be the reason why several immunotherapy trials have had problem with limited responses, since cytotoxic T lymphocytes need an adequate HLA expression level to recognize and kill tumor cells, down-regulation of the expression of HLA molecules on the cell surface may be the answer why the number of durable remissions is low. Down regulation of HLA expression has been demonstrated in many different types of cancer, including skin melanoma (Garrido et al. 1995) (Wang et al. 1996). In uveal melanoma, low expression of HLA-A and -B on the primary tumor has been correlated with

better patient survival (Blom et al. 1997), suggesting a protective role for NK cells which can attack target cells more efficiently in the absence of HLA class I molecules. (Storkus et al. 1987) (Liao et al. 1991). HLA class II antigens have been found in a number of malignancies, although with variable frequency (Pellegrino et al. 1982). The role of HLA class II antigens in the immunologic interaction of malignant cells is conflicting (Seliger et al. 2000).

Chromosomal aberrations

It is well known that mutations within the cell genome cause cancer (Tannock et al. 1992). The observation that chromosomal abnormalities are observed in many types of cancer supports this hypothesis (Tannock et al. 1992). Chronic myeloid leukemia (CML) was the first malignancy in which reproducible chromosomal abnormality was described, the Philadelphia chromosome (Ph chromosome) (Rowley 1973) A number of specific, non-random chromosome abnormalities have now been identified in a variety of malignancies since the detection of the Ph chromosome. In skin melanoma a large number of studies have been made concerning cytogenetic changes, in summary, the highest frequencies of aberrations are seen in chromosomes 1, 6, 7, 9 and 11 (Fountain et al. 1990) (Albino et al. 1993) (Thomson et al. 1995) In uveal melanoma, several recurrent chromosomal abnormalities have been described. Monosomy 3, abnormalities of chromosome 6 and/ or gain of the q arm of chromosome 8 is observed in most tumors (Horsman et al. 1993) (Prescher et al. 1995) (Sisley et al. 2000). Loss of chromosome 3 and gain of the q arm of chromosome 8 associate strongly with decreased survival of the patient (Prescher et al. 1996) (Sisley et al. 1997). In contrast, chromosome 6 abnormalities are associated with a better prognosis (White et al. 1998).

Growth factors

Growth factors are molecules that participate in the control of cell proliferation. They require specific receptors on the target cell and intracellular signaling pathways to transmit the stimulus to the nucleus, where DNA synthesis takes place preceding cell division.

One family of molecules critical for malignant transformation and metastasis are the peptide growth factors that regulate cell entry into and progression through the cell cycle by binding to membrane receptor tyrosine kinases, which transmit signals to the nucleus through an intricate network of signaling molecules (Pardee 1989) (Yarden et al. 1988) (Pawson 1995) Two such subfamilies are the insulin receptor (IR) and the platelet derived growth factor receptor (PDGFR) subfamily. The major feature that separates members of the IR subfamily from most other receptor families is that they exist on cell surface as disulphide linked dimers and require domain rearrangement on binding ligand, rather than receptor oligomerisation, to initiate signal transduction.

One member of the IR subfamily is the insulin-like growth factor-1 receptor (IGF-1R) which is a receptor tyrosine kinase implicated in the induction and maintenance of the transformed phenotype. This heterotetrameric receptor consists of two 130 kDa α -chains and two 90 kDa β -chains, with several α - α and α - β disulfide bridges. (Massague et al. 1982) (Ullrich et al. 1986). The ligand binding domain is located on the extracellular α -subunit. The intracellular region of the β -subunit has a binding site for phosphorylation substrates. The IGF-1R ligands include IGF-1, IGF-II and insulin, but it binds IGF-1 with the highest affinity (LeRoith et al. 1992). The primary physiological role of the insulin receptor is to regulate metabolic events, while the IGF-1R activated by its ligands has a major impact on mitogenicity, transformation and survival (Baserga et al. 1997). In addition, signaling by the IGF-1 receptor is implicated in

the chemotactic activity of tumor (Brodt et al. 2000). Binding and physiological activities of IGF-1 can be modulated by its association with the IGF-binding proteins (IGFBPs), a family of structurally related proteins that bind both IGF-I and IGF-II with high affinities and regulate their biological accessibility and activity (Sara et al. 1990) (Clemmons 1998). The IGF-1 receptor plays an important role in the regulation of the cell cycle (Baserga et al. 1997). During postnatal development and longitudinal growth, growth hormone functions are mediated via IGF-1R. IGF-1 serum levels are high during childhood, declining progressively after puberty. IGF-1R mRNA levels also decline considerably after puberty, remaining high in selected tissues such as the brain and kidney (LeRoith et al. 1992). Malignant transformation, however, is often associated with up-regulated expression and/or constitutive activation of the IGF-1R (Rubin et al. 1995). In response to ligand binding the intrinsic tyrosine kinase of the receptor is activated, resulting in autophosphorylation of tyrosines on the intracellular portion of the β -subunit and the subsequent tyrosine phosphorylation of several downstream substrates including the insulin receptor substrates (IRS 1-4) and Shc (Butler et al. 1998) (Petley et al. 1999). The main pathway for the antiapoptotic effect of the IGF-1R is the pathway that through IRS-1 activates phosphatidylinositol 3-kinase (PI3K) (Myers et al. 1993) and through Akt/ protein kinase B (PKB) induces phosphorylation of BAD (Datta et al. 1997). However alternative pathways have also been found for protection of apoptosis that are independent of the IRS-1 pathways. The pathways suggested are one through mitogen-activated protein kinase (MAPK) activation and another through the activation of Raf-1 and its translocation to the mitochondria (Fig. 3) (Peruzzi et al. 1999). Several lines of evidence implicate IGF-1 and IGF-1R in malignant progression. Increased expression of IGF-1, IGF-1R, or both has been documented in many human malignancies including cutaneous melanoma (Kanter-Lewensohn et al. 1998)

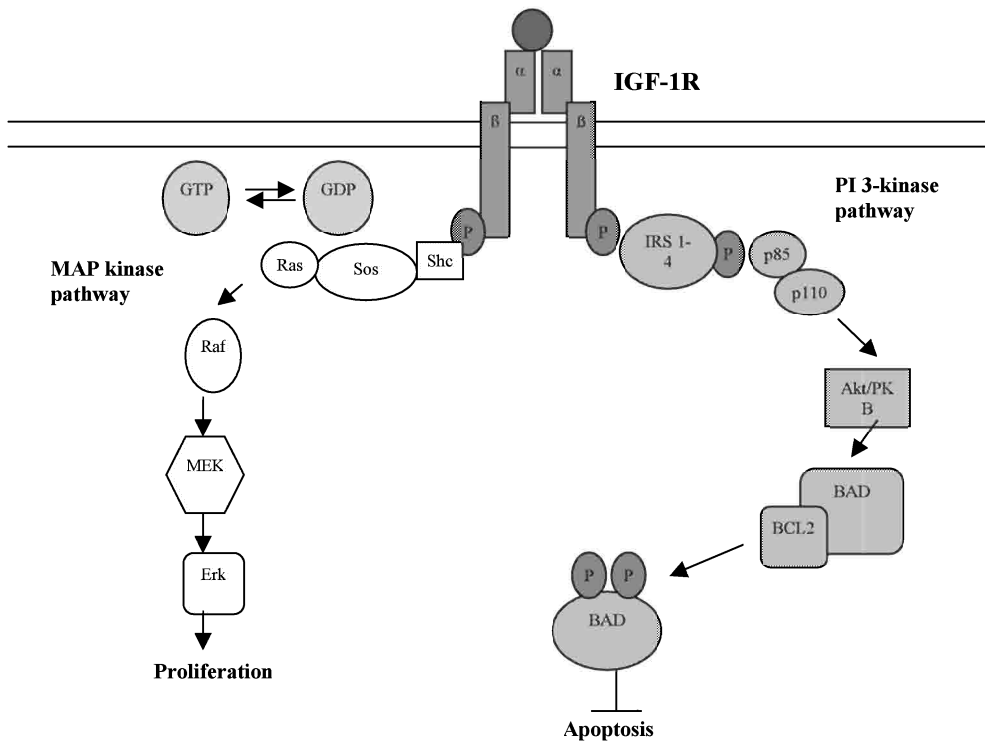


Fig. 3. Simplified presentation of the IGF-1R signaling pathways. The activating of the IGF-1R phosphorylates a number of adaptor proteins and thereby triggering the two major signaling cascades, the MAP-kinase and the PI3-kinase pathways.

Another transmembrane receptor tyrosine kinase is the proto-oncogene c-kit. C-kit is related to the PDGF family (Yarden 1987). Protein activation through the kit ligand (also called stem cell factor (SCF), steel factor or mast cell factor) results in phosphorylation of the receptor as well as other proteins (Williams 1990) (Zsebo et al. 1990). Kit is expressed by and critical in the development of melanocytes, mast cells, hematopoietic stem cell, germ cells and the interstitial cells of Cajal (Funasaka et al. 1992) (Natali et al. 1992) (Larue et al. 1992) (Lassam et al. 1992) (Huizinga 1995). In embryonic development, c-kit is important for normal melanocyte development and proliferation (Yoshida et al. 1993) (Zakut et al. 1993), and e.g. mutations in c-kit or its ligand results in white spotting in mice and humans (Geissler et al. 1988) (Spritz et al. 1993). In addition, injection of anti-KIT antibodies into pregnant mice results in white spotting in offspring (Yoshida et al. 1993). Because of the established relationship of c-kit and its ligand with melanogenesis, the role of this proto-oncogene in the development and progression of human malignant melanoma has become of interest. Specific mutations in the c-kit gene have been found in myeloproliferative disorders (Nakata et al. 1995), mast cells neoplasms (Nagata et al. 1995), seminoma (Tian et al. 1999) and in acute myeloid leukemia (Gari et al. 1999). Mutations in the juxtamembrane domain (exon 11) of the c-kit gene have been shown in gastrointestinal stromal tumors (GISTs) (Hirota et al. 1998) and in a mast-cell leukaemia cell line (Furitsu et al. 1993). The juxtamembrane domain

mutations have been shown to lead to ligand-independent activation (autophosphorylation) of the tyrosine kinase of c-kit and have a transforming effect in vitro (Hirota et al. 1998). Recent data from studies on GISTs have shown that treatment with the phenylamino-pyrimidine derivate STI571 inhibits the tumor growth when treated with the drug at well-tolerated doses

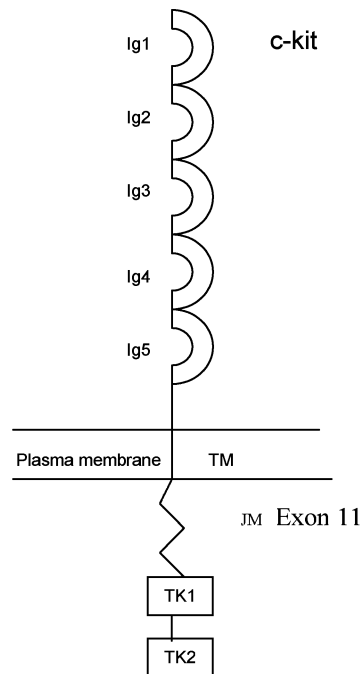


Fig. 4. A schematic drawing of c-kit with five immunoglobuline –like domains (Ig 1-5) in the extracellular ligand binding region, a single transmembrane domain (TM), a juxtamembrane domain (JM), two intracellular kinase domains (TK1 and TK2). The position for exon 11 is highlighted.

AIMS OF THE STUDY

To determine which chromosomal aberrations could be involved in the development of metastases in uveal melanoma using CGH technique.

To investigate if the expression of the different HLA classes are correlated to the clinical outcome of uveal melanoma using different monoclonal antibodies.

To evaluate if the IGF-1 receptor is expressed in uveal melanoma and if it is important for tumor growth.

To investigate if the proto-oncogene c-kit is expressed in uveal melanoma and if tumor cell proliferation can be inhibited by the tyrosine kinase inhibitor STI571.

MATERIAL AND METHODS

Clinical material

We used paraffin-embedded archive material from patients treated solely by enucleation. The specimens were submitted from 1970 to 1985. The patients age ranged from 23 to 87 years. In addition fresh frozen samples were used, these were submitted from 1997 to 1999. The patients were selected to form two groups: survivors (alive 15 years or more after enucleation without signs of metastatic disease) and dead (died of metastatic melanoma) (paper I, II and III).

Chemicals

Cell culture reagents were from Gibco. Fluorescein-isothiocyanate-conjugated dCTP and dUTP were from DuPont, (Boston, MA, USA). All other chemicals unless stated otherwise were from Sigma (St Louis, MO, USA). The following antibodies were used: anti HLA-A10, -A28, -A29, -A30, -A31, -A32, -A33 heavy chains and virtually all HLA-B heavy chains (HC-10), anti- β 2-m (L368), anti-HLA class II (LGII-612) were developed and characterized as described elsewhere (Stam et al. 1986) (Lampson et al. 1983) (Temponi et al. 1993), anti-CD44 (IM-79, American Type Culture Collection, Rockville, USA), a monoclonal antibody to the β subunit of the IGF-1R phosphotyrosine (PY99) and a polyclonal antibody to IGF-1R (N-20, SDS, Santa Cruz Biotechnology Inc., Santa Cruz, CA, USA) a mouse monoclonal antibody against human IGF-1R (α IR-3, Oncogen Science, NY, USA). A mouse monoclonal antibody directed to the human c-kit (CD117) was purchased from Dako (CA, USA). STI571 was obtained from Novartis (Basel, Switzerland)

Cells

Four cell lines, obtained from human primary uveal melanomas (OCM-1, OCM-3, Mel-202 and 92-1), were used. They were kindly provided by Dr Martine J. Jager (Leiden University Medical Center, Leiden, The Netherlands).

Immunohistochemistry

Immunostaining was performed using the standard Avidin-Biotin-immunoperoxidase Complex (ABC) method (Vector Laboratories, Burlingame, CA, USA), on 4- μ m thick sections. Deparaffinized, rehydrated sections were pretreated with microwaves for 10 min in citrate buffer (pH 6.0) (paper III and IV) or digested with 0.05% pronase for 15 min (paper III). No antigen retrieval was performed before the antibody incubation in paper II. Before immunostaining the endogenous peroxidase was blocked with hydrogen peroxidase dissolved in methanol for 30 min. Tissue sections were then rinsed and incubated with blocking serum (1% bovine serum albumin) for 20 min followed by an overnight incubation at 8°C with the primary antibodies. A biotinylated antimouse or antirabbit IgG antibodies were used as a secondary antibody and followed by the ABC. 3,3'-diaminobenzidine tetrahydrochloride (DAB) was used as chromogen and counterstaining was performed by Mayer's hematoxylin. TRIS-PBS (pH 7.6) was used for rinsing between the different steps.

Cell culture

The OCM-1 cells were cultured in Dulbecco's modified Eagle's medium (DMEM) supplemented with 10% fetal bovine serum (FBS), and the Mel-202, OCM-3 and 92-1 cells in RPMI 1640 supplemented with 10% FBS and 3 mM L-glutamine. Cells were grown in monolayers in tissue culture flasks, maintained in a 95% air/5% CO₂ atmosphere at 37°C in a humidified incubator. For experimental purposes the cells were cultured in 35- or 60-mm plastic Petri dishes. Cells were seeded at a density of 3000-5000 cells / cm² and experiments were initiated when cells had reached subconfluence.

Assay of cell growth and survival

In order to determine DNA synthesis in paper III, cells were cultured in 35-mm dishes and, after the experimental conditions, labeled with [³H]thymidine (1 μCi/ml, 5 Ci/mmol) for 4 h. The acid-precipitable material was then taken for scintillation counting as described elsewhere (Carlberg et al. 1996). Cell proliferation was measured by determining the number of cells attached onto the plastic surface of duplicate 35-mm dishes. This was performed by microscopic counting of all cells in ink-marked areas on the dish bottom. By repeating the counting after specified time intervals, changes in the number of attached cells could be followed (Dricu et al. 1997).

Isolation of cell membranes

Preparation of cell membranes was performed essentially as described elsewhere (Gammeltoft 1990). In brief, cells were harvested and homogenized in a buffer containing 0.32 M sucrose, 1 mM taurodeoxycholic acid, 2 mM MgCl₂, 1mM EDTA, 25 mM benzamidine, 1 μg/ml bacitracin, 2 mM phenylmethylsulfonyl fluoride, 10 μg/ml aprotinine, 10 μg/ml soyabean trypsin inhibitor and 10 μg/ml leupeptin. After a 10-min centrifugation at 600 x g (4°C) the pellet (containing unbroken cells, nuclei and cytoskeleton) was discarded. The supernatant was then centrifuged at 17,300 x g for 30 min. The resulting pellet, contained cell membranes, and the supernatant represented the intracellular compartment containing endoplasmatic reticulum, Golgi complex and other organelles.

Determination of protein content

Protein content of cell lysates was determined by dye-binding assay (Bradford 1976) with a reagent purchased from Bio-Rad. Bovine serum albumin was used as a standard.

Cell viability assay

In paper III and IV cell proliferation kit II was used (Roche Diagnostic GmbH Mannheim, Germany). The test is based on a colorimetric change of the yellow tetrazolium salt XTT into orange formazan dye by the respiratory chain of viable cells (Roehm et al. 1991). Cells seeded at a concentration of 5000/well in 100 μl medium in a 96-well plate were treated with different drugs in specified concentrations. After 24 h, cells were incubated according to the manufacturer protocol with XTT labeling mixture. After 4 h, the formazan dye was quantified using a scanning multiwell spectrophotometer with a 495-nm filter. The absorbance is directly correlated with the number of viable cells. In order to draw the standard absorbance curve, we used untreated cells seeded at concentrations from 1000 to 10,000 cells/ well with an

increasing rate of 1000 cells/ well. All standards and experiments were performed in triplicates.

Immunoprecipitation

Cells were washed twice with phosphate-buffered saline (PBS) and then lysed in PBS/TDS containing the aforementioned protease inhibitors. The lysates were clarified by centrifugation. Protein samples were incubated with 10 µl of each analyzed antibody. To 1 ml lysate was added 15 µl Protein G Plus-Agarose. After overnight incubation at 4°C on a rocker platform, the immunoprecipitates were collected by centrifugation in a microcentrifuge at 2,500 rpm for 15 min. The supernatant was discarded whereupon the pellet was washed four times with 1 ml PBS/TDS. The material was then dissolved in sample buffer for SDS-PAGE.

Sodium dodecyl sulphate polyacrylamide gel electrophoresis (SDS-PAGE)

Protein samples were dissolved in a sample buffer containing 0.0625 M Tris -HCl, (pH 6.8), 20% glycerol, 2% sodium dodecyl sulfate (SDS), bromophenol blue and dithiothreitol. Sample amounts obtained from 50 µg – 1mg total cell proteins were analyzed by SDS-PAGE with a 4% stacking gel and a 10% separation gel, essentially according to protocol the of Laemmli (Laemmli 1970). Molecular weight markers (Bio-Rad) were run simultaneously.

Western blotting

Following SDS-PAGE the proteins were transferred overnight to nitrocellulose membranes (Hybond, Amersham) and then blocked for 1h at room temperature in a solution of 5% (w/v) skimmed milk powder and 0.02% (w/v) Tween 20 in PBS, pH 7.5. Incubation with the primary antibody, was performed for 1 h at room temperature. This was followed by three washes with PBS and incubation with a biotinylated secondary antibody (Amersham) for 1 h. After a 15-min incubation with streptavidin-labeled horse peroxidase, detection was performed by enhanced chemiluminescence. Signal was detected with Hyperfilm-ECL (Amersham).

Comparative genome hybridization (CGH)

CGH was performed as described previously (Kallioniemi et al. 1994) (El-Rifai et al. 1997). Tumor DNA and normal reference DNA were labeled by nick-translation with fluorescein-isothiocyanate-conjugated dCTP and dUTP (DuPont, Boston, MA, USA) and Texas-red conjugated dCTP and dUTP (DuPont) The hybridization was analyzed using an Olympus fluorescence microscope mounted to a CCD camera and the ISIS digital image analysis system (MetaSystems, Altussheim, Germany). Three-color images (green for tumor DNA, red for reference DNA and blue for chromosome counterstaining) were acquired from 8 to 10 metaphases with strong uniform hybridization. Chromosome regions were interpreted as overrepresented when green-to-red ratio was higher than 1.17 (gains) and underrepresented when ratio was lower than 0.85 (losses). A ratio value higher than 1.15 was used to define a high-level amplification.

PCR amplification and sequencing analysis

DNA was isolated from frozen uveal melanoma specimens by standard methods. We used a nested polymerase chain reaction (PCR) method to amplify genomic fragments of exon 11 using primers annealing the intronic regions that flank exon 11 of the c-kit gene. Shortly, 500 ng of genomic DNA was amplified using 5' (GTATGCCACATCCCAAGTGTT) and 3' (CCTGACAGACAATAAAAGGCAGC) primers in a 35 cycles reaction of 94° for 30 sec; 52° for 45 sec, and 68° for 2 min. For the nested PCR, the primers 5' (CGACTCGATCCCATCCTGCC); and 3' (CAAAGGAAGCCACTGGAGTTCC) were used in a 34 cycles PCR of 94° for 30 sec, 56° for 45 sec, and 70° for 45 sec. The PCR products were electrophoresed in a 1% agarose gel containing ethidium bromide, and visualized in a UV camera prior to sequencing in a ABI PRISM 310 DNA sequencer using Big Dye terminators (Applied Biosystems, Foster City, CA, USA). The sequences obtained were identified and aligned together with the human c-kit gene sequence obtained from the Genbank (National Center for Biotechnology Information) and analysed using the Sequencher program (Gene Codes).

Statistical evaluation

In paper I the Mann-Whitney test was used to compare the number of aberrations and the frequency of individual changes between different tumor types. In paper II and III time from the date of surgery to death or the end of 1996 was considered censored if the patient was alive at the end of 1996 or had died of any other than a melanoma-related cause. The log-rank test was used to assess survival differences. In paper II the χ^2 test was used to measure association of HLA antigen expression with metastasis development and cell type. In paper II and III the kappa test was used for assessing the inter-observer reproducibility. The significance level was set at 0.05. Calculations were computer based, using Statistica version 5.5 (StatSoft, Tulsa, OK) and MedCalc (MedCalc Software, Mariakerke, Belgium).

RESULTS

Paper I

We studied if there are any genetic differences between metastasizing and non-metastasizing uveal melanoma by using CGH technique. 29 of 35 tumors showed DNA copy number changes. We found that primary uveal melanomas that had metastasized and metastases had significantly more changes than primary uveal melanomas that had not metastasized. Comparison between primary non-metastasizing tumors, metastasizing tumors, and metastases showed that the most common DNA copy number changes were losses of chromosome 3 (21%/73%/67%, respectively), 6q (7%/40%/83%), 1p (0%/33%/33%), 13q (14%/13%/50%), 8p (14%/27%/0%), and 18 (7%/13%/33%), and gains at chromosome 8q (14%/53%/100%), 6p (29%/20%/17%), 1q (0%/7%/33) and 16p(0%/7%/33%). The mean number of DNA copy number changes was significantly higher in the metastasizing tumors and in metastases than in non-metastasizing tumors ($P<0.05$). There were no significant difference in the DNA copy number changes between metastasizing tumors and metastases.

Paper II

Malignant transformation of cells is frequently associated with abnormalities in human leukocyte antigen (HLA) expression. In this study we immunoperoxidase stained 65 formalin-fixed paraffin-embedded primary uveal melanoma lesions with anti-HLA class I, anti- β_2 -microglobuline and anti-HLA class II mAbs. We found that HLA class I and β_2 -m expression were downregulated in 62% (40/65) and 54% (35/65) of the lesions respectively. High levels of HLA class II antigens were expressed in 46% (30/65) of the lesions respectively. HLA class I antigen, β_2 -m and HLA class II antigen expression in the 65 primary uveal melanoma lesions was associated with poor clinical outcome. Thus, high expression of these markers in the lesions was significantly ($P=0.013$, $P<0.001$ and $P=0.021$, respectively) correlated with development of metastases

Paper III

In an increasing number of malignant cell types IGF-1R has been proven essential for tumorigenesis as well as for the establishment and maintenance of a transformed phenotype. In this study we wanted to elucidate if IGF-1R is expressed in uveal melanoma, and if the expression is correlated to clinical behaviour, cell growth and survival of uveal melanoma cells. We were able to confirm a expression of IGF-1R in uveal melanoma both in paraffin embedded tumor specimens by immunohistochemistry and by Western blotting on fresh frozen samples. Using Kaplan Meier statistical analysis we found a significant association between high IGF-1R expression and death due to uveal melanoma ($P = 0.035$).

In the second part of this study, we investigated the expression of IGF-1R in the three uveal melanoma cell lines OCM-1, OCM-3 and 92-1 and how modulation of IGF-1R expression affected cell growth and survival. We found that inhibition of the IGF-1R activity (tyrosine phosphorylation) was associated with a drastic decrease in uveal melanoma cell viability.

Paper IV

For several malignant tumors the expression of the proto-oncogene c-kit is important in tumor progression. Since a c-kit inhibitor is provided for clinical use the aim of paper IV was to evaluate if c-kit is expressed in uveal melanoma and if it would be possible to inhibit tumor growth by the inhibitor STI571.

First we investigated the expression of c-kit by immunohistochemistry on paraffin-embedded surgical specimens of 134 cases of primary uveal melanoma. Positive immunoreactivity was found in 84 of the cases. The expression level regarding intensity was scored no, low, medium and high staining as described in Material and methods. To further confirm the results we also investigated the expression of c-kit on eight fresh-frozen samples from primary uveal melanoma, on two uveal melanoma cell lines and six skin melanoma samples by Western blotting using an antibody specific for c-kit (CD117), six of the uveal melanoma cases and both cell lines resulted in a positive signal but none of the skin melanoma samples could be shown to express c-kit. To study the anti-proliferative effects of the tyrosine kinase inhibitor STI571 we treated four uveal melanoma and two skin melanoma cell lines. Cell proliferation was completely inhibited after 48h by 1 μ M STI571 in the uveal melanoma cell lines but not in the skin melanoma cell lines. Chromosomal analysis failed to detect any mutations on exon 11 in this material.

DISCUSSION

Distant metastases, probably seeded before treatment of the primary tumor, could possibly explain the high incidence of tumor related death in uveal melanoma. It is well known that the incidence of metastases at the time of presentation is very low, only 2% (Pach et al. 1986). At present we neither have the techniques to identify the patients who are of greatest risk to develop metastases nor do we have any effective treatment to offer them. It is thus of great importance to find factors that at an early stage can help us identify and treat them.

For the purpose of predicting prognosis based on chromosomal aberrations we screened uveal melanoma samples for DNA copy number changes by CGH and looked at the copy number changes between non-metastasizing and metastasizing tumors. Previous chromosome banding analysis and loss of heterozygosity studies fitted well with our findings that losses of chromosome 3 and gains of chromosome 8 are signs of poor prognosis (Horsthemke et al. 1992) (Prescher et al. 1996) (Sisley et al. 1997) (White et al. 1998). Two recently published studies have shown that this knowledge may be useful clinically since it is easily possible to use FISH on both fresh frozen material from enucleated eyes (Patel et al. 2002) and on fine needle aspiration biopsies (FNABs) from patients solely treated by radiotherapy (with or without transpupillary thermotherapy) (Naus et al. 2002) for assaying prognostic parameters such as chromosome 3 loss and/or chromosome 8q gain. The most common aberration in skin melanoma, loss of chromosome 9p21 which have been suggested to be the familial melanoma gene have not been found in this or in any other published study. Uveal melanoma is not an inherited tumor in most cases. We also found that the frequency of copy number changes is significantly higher in metastasizing tumors and metastases than in non-metastasizing tumors. The loss of 1p, with minimal overlapping region at 1p21-p23, could only be detected in metastasizing tumors suggesting that this region may harbor a tumor suppressor gene (TSG) important for tumor progression. Deletions of 1p are common in several other human neoplasms, but to my knowledge has no TSGs of any importance for uveal melanoma yet been mapped to this specific region. Presence of chromosome 6 abnormality has been observed to improve prognosis (White et al. 1998). We found a significantly higher frequency of chromosome 6q losses in metastasizing primary tumors and metastases than in non metastasizing tumors and a trend towards more gains of 6p in non-metastasizing tumors.

Aberrations on chromosome 6 could possibly be correlated to the human leukocyte antigen (HLA) expression since the genes for the HLA class I α chain (the beta-2-microglobulin(β 2m) gene is localized to chromosome 15q22) and HLA class II are both located in the 6p21.3 region on the short arm of chromosome 6. However has that connection been refuted in both skin and uveal melanoma (Jiminez et al. 1999) (Metzelaar-Blok et al. 1999).

In skin melanoma and many other human tumors, changes in the expression and/or function of HLA class I antigens may provide malignant cells with mechanisms to escape from T-cell recognition and destruction (Garrido et al. 1997) (Hicklin et al. 1999) (Koopman et al. 2000) (Marincola et al. 2000). This abnormality might adversely affect the clinical course of the disease and the outcome of immunotherapy. The association between high HLA class I antigen expression in primary lesions and poor prognosis we, as well as Blom et al (Blom et al. 1997), found in patients with uveal melanoma is contrary to what has been found in skin melanoma and in other types of malignancies. In uveal melanoma, the association of low HLA class I antigen expression in primary lesions with favorable clinical course of the disease may reflect the susceptibility to NK cell mediated lysis of low HLA class I expressing

melanoma cells invading blood vessels, as proposed by Blom et al (Blom et al. 1997). If this interpretation is correct, NK cells may be particularly important in tumors spreading hematogenously, while playing less of a role in tumors spreading via the lymphatic system. Several studies on mice have confirmed this theory (Algarra et al. 1989; Ma et al. 1995) even though uveal melanoma seems to have evolved other means to escape NK mediated surveillance, including production of a macrophage-inhibitory factor which prevents lysis by NK cells (Repp et al. 2000). HLA class II antigens were detected in a significantly higher percentage of primary uveal melanoma lesions than that reported by Jager et al (Jager et al. 1988). Although one cannot exclude that this reflects differences in the sensitivity of the immunohistochemical assays used in the two studies, we favor the possibility that the low HLA class II antigen expression described by Jager et al (Jager et al. 1988) is caused by the exposure of the uveal melanoma analyzed to x-ray irradiation prior to enucleation. Our interpretation is supported by the correlation found in another study between HLA-DQ expression in a uveal melanoma and a ciliary body localization of the tumor and between a low HLA-DQ and -DP expression and an intact Bruch's membrane (de Waard-Siebinga et al. 1996). HLA class II antigen expression in primary uveal melanoma lesions has clinical significance, since none of the patients lacking HLA class II antigen expression in their primary lesions (14 cases) died from uveal melanoma. In contrast, 18 of the 30 patients with high HLA class II antigens died from uveal melanoma. It has been demonstrated that HLA class II antigen bearing melanoma cells induce the secretion of immunosuppressive cytokine IL-10 by T cells resulting in T cell anergy (Brady et al. 2000) which may explain the association between high HLA class II antigen expression in primary uveal melanoma lesions and poor prognosis. Alternatively, the observed correlation may reflect the resistance of hematogenously spreading melanoma cells with high HLA class I as well as HLA class II antigen expression to NK cell lysis, since HLA class I and HLA class II antigens may share a common regulatory pathway (van den Elsen et al. 1998) and the expression of these molecules were found to be correlated in our study.

Receptor tyrosine kinases play a role in normal cellular regulatory processes. However, aberrant tyrosine kinase activity can lead to cellular transformation and can be causally associated with tumor maintenance and progression. Previous studies on uveal melanoma have shown that the expression of epidermal growth factor receptor (EGFR) was significantly correlated with death due to metastatic disease and decreased survival (Ma et al. 1998) (Hurks et al. 2000). Although conflicting data also has been reported, stating that the expression of EGFR in uveal melanoma was only due to macrophages (Scholes et al. 2001). In several cell types, IGF-1R has been shown to play a pivotal role in cell cycle regulation, differentiation, apoptosis protection as well as in cell transformation (Harrington et al. 1994) (Kalebic et al. 1994) (Prager et al. 1994) (Resnicoff et al. 1994) (Resnicoff et al. 1994) (Shapiro et al. 1994) (Baserga 1995) (Resnicoff et al. 1995) (Sell et al. 1995). Furthermore, a high expression has been shown to be correlated with a poor clinical outcome in certain cancers. Xie et al recently demonstrated that metastatic dissemination of synovial sarcoma, a highly malignant soft tissue tumor, was significantly correlated with a high expression of IGF-1R in the localized tumor, as assayed by both RT-PCR and Western blotting (Xie et al. 1999). Egan et al have reported the importance of IGF-1 and its serum binding protein, IGFBP-3, both of which were found to independently predict metastasis in choroidal melanoma (Egan et al. 2000). However, as stated by Baserga, IGF-1 (or IGF-2) can stimulate the growth of tumors but it is the receptor that defines the outcome, and presence of an IGF-1R is obligatory for malignant transformation (Baserga 1999).

From our study we can conclude that IGF-1R is expressed to a variable extent in uveal melanoma (based on a selected sample) and that high expression of IGF-1R is associated with

a decreased survival in this disease. From our study we can also conclude that growth and survival of uveal melanoma cell lines are strongly dependent on IGF-1R expression and activation. Specifically, we have shown that inhibition of N-linked glycosylation induced by treatment with tunicamycin (TM) and lovastatin caused decreased IGF-1R expression, and consequently decreased IGF-1R tyrosine phosphorylation. Subsequently, this induced growth arrest and cell death in the three investigated uveal melanoma cell lines. In this way treatment with TM and lovastatin simulate the effect of growth factor depletion, which in itself induces apoptosis in tumor cells (Evan et al. 1992). It could be argued that lovastatin and TM kill the cells by other mechanism than by down-regulating the IGF-1R. However, as shown in this study and in others (Dricu et al. 1997) (Dricu et al. 1999) (Gimira et al. 2000), the kinetics of the growth inhibition and cell death correlate well with the effects obtained by the decrease in IGF-1R tyrosine phosphorylation using the IGF-1R blocking monoclonal antibody α IR-3 (Fig 4).

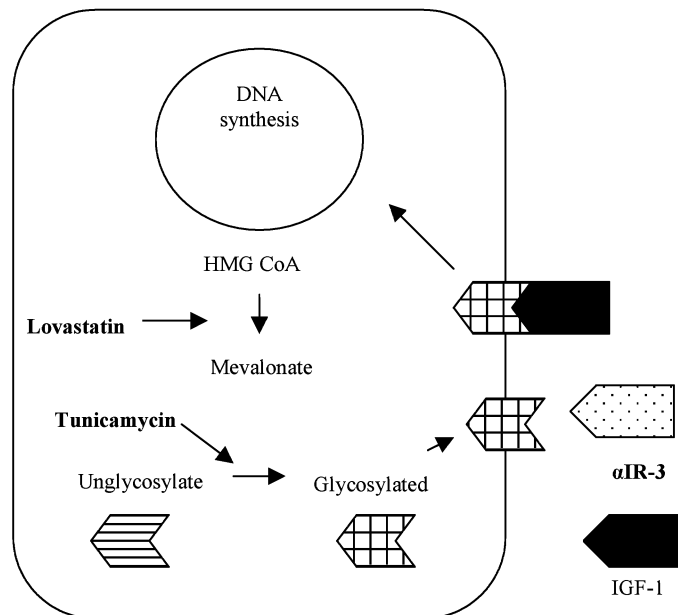


Fig 4. A scheme showing where lovastatin, tunicamycin and α IR-3 interfere with IGF-1R. Lovastatin is an inhibitor of HMG-CoA reductase, the enzyme that catalyzes the conversion from HMG-CoA to mevalonate. Tunicamycin, a nucleoside antibiotic, inhibits the glycosylation. α IR-3 is a monoclonal antibody against the binding domain at IGF-1R.

Somatostatin and its analogs can inhibit growth by interfering with IGF-1 signaling in normal and malignant cells (Reubi et al. 1995). Down regulation of IGF-1 (Yumi et al. 1997), upregulation of the expression of inhibitory IGF-1-binding proteins (Ren et al. 1992), and inhibition of the mitogenic signalling via the IGF-1R (Grant et al. 1993) (Cattaneo et al. 1996) have been reported as plausible mechanisms mediating the growth inhibitory effect of somatostatin analog octreotide. Our results, that uveal melanoma expresses IGF-1R and that inhibition of its function leads to growth arrest and cell death, theoretically support the indication of somatostatin IGF-1 inhibition of uveal melanoma.

The proto-oncogene *c-kit* encodes a transmembrane tyrosine receptor whose expression is lost or upregulated in a wide variety of human malignancies. The kinase activity has been implicated in the pathophysiology of a number of these tumors, including GISTs, neuroblastoma and skin melanoma. In skin melanoma, *c-kit* is expressed in epidermal melanocytes but in primary melanomas loss of the receptor is observed in more invasive lesions, only 30% of them express *c-kit* (Lassam et al. 1992) (Natali et al. 1992). Contradictory to a previous study, which failed to detect expression of *c-kit* in the uveal melanoma cell line OCM-1 (Mouriaux et al. 2001), we have shown using both IHC and Western blotting that *c-kit* is expressed in uveal melanoma. Binding of stem cell factor (SCF) to *c-kit* results in receptor homodimerization, activation of *kit* tyrosine kinase activity and resultant phosphorylation of a variety of substrates. Former studies on skin melanoma have shown that *c-kit* expression is regulated by the transcription factor AP-2 (Bar-Eli 2000). Interestingly, AP-2 has been shown to regulate the expression of both *c-kit* and IGF-1R (van den Oord et al. 1994) why AP-2 can be an interesting target for future investigation. The tyrosine kinase activity of *kit* can be activated by mutation of several different exons of the *c-kit* gene. The juxtamembrane region of *kit* (exon 11) serves as an antidimerization domain. Mutations of this domain result in activation of kinase activity by allowing ligand-independent receptor dimerization (Irusta et al. 1998) (Ma et al. 1999). Mutations in the exon 11 of the *c-kit* gene have been shown in mast cell leukemia cell line (Furitsu et al. 1993) and in GISTs (Hirota et al. 1998). Targeted therapy to inhibit the kinase activity of KIT has been exploited in the successful treatment of GISTs with the phenylpyrimidine STI571 (CGP 57148B, Imatinib mesylate, Gleevec®, Glivec®) (Joensuu et al. 2001). This fact raised the interest whether mutations in exon 11 could be found in uveal melanoma, and if growth arrest could be induced in the uveal melanoma cells by treating them with STI571. We did not detect any mutations in exon 11 of 15 fresh frozen samples. In contrast, we found that treatment with STI571 led to complete cell arrest in all four uveal melanoma cell lines but not in the investigated skin melanoma cell lines. These observations suggest that STI571 may be useful in treatment of metastasizing uveal melanomas overexpressing *c-kit*.

REFERENCES

- (1998). "Histopathologic characteristics of uveal melanomas in eyes enucleated from the Collaborative Ocular Melanoma Study. COMS report no. 6." Am J Ophthalmol **125**: 745-766.
- Albert, D. M., et al. (1992). "Treatment of metastatic uveal melanoma: review and recommendations." Surv Ophthalmol **36**: 429-438.
- Albino, A., et al. (1993). "Molecular genetics of human malignant melanoma." Cancer Treat Res **65**: 201-255.
- Algarra, I., et al. (1989). "NK sensitivity and lung clearance of MHC class I deficient cells within a heterogeneous fibrosarcoma." Int J Cancer **44**: 675-680.
- Bar-Eli, M. (2000). "Role of AP-2 in tumor growth and metastasis of human melanoma." Cancer and Metastasis Reviews **18**: 377-385.
- Barr, C. C., et al. (1983). "Recurrence of choroidal melanoma after photocoagulation therapy." Arch Ophthalmol **101**: 1737-1740.
- Baserga, R. (1995). "The insulin-like growth factor-1 receptor:a key to tumor growth." Cancer Res **55**: 249-252.
- Baserga, R. (1999). "The IGF-1 receptor in cancer research." Exp Cell Res **253**: 1-6.
- Baserga, R., et al. (1997). "The IGF-I receptor in cell growth, transformation and apoptosis." Biochim Biophys Acta **1332**: 105-126.
- Bergman, L., et al. (2002). "Incidence of Uveal Melanoma in Sweden from 1960 to 1998." Invest Ophthalmol Vis Sci **43**: 2579-2583.
- Blom, D. J., et al. (1997). "Human leukocyte antigen class I expression. Marker of poor prognosis in uveal melanoma." Invest Ophthalmol Vis Sci **38**: 1865-1872.
- Blom, D. J., et al. (1997). "HLA expression in a primary uveal melanoma, its cell line, and four of its metastases." Br J Ophthalmol **81**: 989-993.
- Bradford, M. M. (1976). "A rapid and sensitive method for the quantification of microgram quantities of protein utilizing the principle of protein dye binding." Anal Biochem. **72**: 248-254.
- Brady, M. S., et al. (2000). "CD4+ T cells kill HLA class II antigen positive melanoma cells presenting peptide in vivo." Cancer Immunol . Immunother. **48**: 621-628.

- Brodt, P., et al. (2000). "Inhibition of the type-1 insulin-like growth factor receptor expression and signaling: novel strategies for antimetastatic therapy." Biochem Pharmacol **60**: 1101-1107.
- Butler, A. A., et al. (1998). "Insulin-like growth factor-I receptor signal transduction: At the interference between physiology and cell biology." Comp Biochem Physiol B Biochem Mol Biol **121**: 19-26.
- Callender, G. (1931). "Malignant melanotic tumors of the eye. A study of histologic types in 111 cases." Trans Am Acad Ophthalmol Otolaryngol **36**: 131-140.
- Cantore, M., et al. (1994). "Intra-arterial hepatic carboplatin-based chemotherapy for ocular melanoma metastatic to the liver. Report of a phase II study." Tumori **80**: 37-39.
- Carlberg, M., et al. (1996). "Mevalonic acid is limiting for N-linked glycosylation and translocation of the insulin-like growth factor-1 receptor to the cell surface. Evidence for a new link between 3-hydroxy-3-methylglutaryl-coenzyme A reductase and cell growth." J Biol Chem **271**: 17453-17462.
- Cattaneo, M. G., et al. (1996). "A somatostatin analogue inhibits MAP kinase activation and cell proliferation in human neuroblastoma and in human small cell lung carcinoma cell lines." FEBS Lett **397**: 164-168.
- Char, D. H. (1978). "Metastatic choroidal melanoma." Am J Ophthalmol **86**: 76-80.
- Char, D. H., et al. (1980). "Helium ion charged particle therapy for choroidal melanoma." Ophthalmology **87**: 565-570.
- Char, D. H., et al. (2001). "Uveal tumour resection." Br J Ophthalmol **85**: 1213-1219.
- Clemmons, D. R. (1998). "Role of insulin-like growth factor binding proteins in controlling IGF actions." Mol Cell Endocrinol **140**: 19-24.
- Coupland, S. E., et al. (1996). "Metastatic choroidal melanoma to the contralateral orbit 40 years after enucleation." Arch Ophthalmol **114**: 751-756.
- Damato, B., et al. (1996). "Indications for trans-scleral local resection of uveal melanoma." Br J Ophthalmol: 1029-1030.
- Das Gupta, T., et al. (1964). "Metastatic melanoma: a clinicopathological study." Cancer **17**: 1323-1339.
- Datta, S. R., et al. (1997). "Akt phosphorylation of BAD couples survival signals to the cell-intrinsic death machinery." Cell **91**: 231-241.
- De Potter, P., et al. (1994). "Impact of enucleation versus plaque radiotherapy in the management of juxtapapillary choroidal melanoma on patient survival." Br J Ophthalmol **78**: 109-114.

- de Waard-Siebinga, I., et al. (1996). "Differential expression of HLA-A and B-alleles on uveal melanoma as determined by immuno-histology." Ocul Immunol Inflamm **4**: 1-14.
- Diener-West, M., et al. (1992). "A review of mortality from choroidal melanoma: A meta-analysis of 5- year mortality rates following enucleation, 1966 through 1988." Arch Ophthalmol **110**: 245-250.
- Dithmar, S., et al. (2000). "Intraocular melanoma spread to regional lymph nodes: report of two cases." Retina **20**: 76-9.
- Dolin, P. J., et al. (1994). "Uveal melanoma: is solar ultraviolet radiation a risk factor?" Ophthalmic Epidemiol **1**: 27-30.
- Dricu, A., et al. (1997). "Inhibition of N-linked glycosylation using tunicamycin causes cell death in malignant cells: role of down-regulation of the insulin-like growth factor-1 receptor in induction of apoptosis." Cancer Res **57**: 543-548.
- Dricu, A., et al. (1999). "Expression of the insulin-like growth factor-1 receptor (IGF-1R) in breast cancer cells: evidence for a regulatory role of dolichyl phosphate in the transition from an intracellular to an extracellular IGF-1 pathway." Glycobiology **9**: 571-579.
- Egan, K. M., et al. (2000). "Role of serum insulin-like growth factor-1 (IGF-1) in the progression of choroidal melanoma (ARVO Abstract)." Invest Ophthalmol Vis Sci: 41(4):S382. Abstract nr 2017.
- Egan, K. M., et al. (1988). "Epidemiologic aspects of uveal melanoma." Surv Ophthalmol **32**: 239-251.
- Einhorn, L. H., et al. (1974). "Metastatic patterns of choroidal melanoma." Cancer **34**: 1001-1004.
- El-Rifai, W., et al. (1997). "Optimization of comparative genomic hybridization using fluorochrome conjugated to dCTP and dUTP nucleotides." Lab Invest **77**: 699-700.
- Evan, G. I., et al. (1992). "Induction of apoptosis in fibroblasts by c-myc protein." Cell **69**: 119-128.
- Ferrone, S., et al. (1995). "Loss of HLA class I antigens by melanoma cells: molecular mechanisms, functional significance and clinical relevance." Immunol Today **16**: 487-494.
- Finger, P. T., et al. (1994). "Palladium 103 plaque radiotherapy for uveal melanoma. Clinical experience." Ophthalmology **101**: 256-263.

- Folberg, R., et al. (2001). "Microcirculation patterns other than loops and networks in choroidal and ciliary body melanomas." *Ophthalmology* **108**: 996-1001.
- Folberg, R., et al. (1992). "The morphologic characteristics of tumor blood vessels as a marker of tumor progression in primary human uveal melanoma: a matched case-control study." *Hum Pathol* **23**: 1298-1305.
- Folberg, R., et al. (1993). "The prognostic value of tumor blood vessel morphology in primary uveal melanoma." *Ophthalmology* **100**: 1389-1398.
- Foulds, W. S. (1973). "The local excision of choroidal melanomata." *Trans Ophthalmol Soc U K* **93**: 343-346.
- Fountain, J., et al. (1990). "Genetics of melanoma." *Cancer Surv* **9**: 645-671.
- Fuchs (1882). "Das Sarcom des Uvealtractus."
- Funasaka, Y., et al. (1992). "c-kit kinase induces a cascade of protein tyrosine phosphorylation in normal human melanocytes in response to mast cell growth factor and stimulated mitogen-activated protein kinase but is down-regulated in melanomas." *Mol Biol Cell* **3**: 197-209.
- Furitsu, T., et al. (1993). "Identification of mutations in the coding sequence of the proto-oncogene c-kit in a human mast cell leukemia cell line causing ligand-independent activation of c-kit product." *J Clin Invest* **92**: 1736-1744.
- Gamel, J. W., et al. (1992). "A comparison of prognostic covariates for uveal melanoma." *Invest Ophthalmol Vis Sci* **33**: 1919-1922.
- Gamel, J. W., et al. (1993). "Biologic distinctions between cure and time to death in 2892 patients with intraocular melanoma." *Cancer* **71**: 2299-2305.
- Gammeltoft, S. (1990). Peptide hormone receptors. *Peptide hormone action. A practical approach*. K. Siddle and J. C. Hutton. Oxford, Oxford University Press: 1-41.
- Gari, M., et al. (1999). "C-kit proto-oncogene exon 8 inframe deletion plus insertion mutations in acute myeloid leukaemia." *Br J Haematol* **105**: 894-900.
- Garretson, B. R., et al. (1987). "Choroidal melanoma treatment with iodine 125 brachytherapy." *Arch Ophthalmol* **105**: 1394-1397.
- Garrido, F., et al. (1995). "HLA class I antigens in human tumors." *Adv. Cancer Res.* **67**: 155-195.
- Garrido, F., et al. (1997). "Implications for immunosurveillance of altered HLA class I phenotypes in human tumours." *Immunol Today* **18**: 89-95.

- Gass, J. D. (1977). "Problems in the differential diagnosis of choroidal nevi and malignant melanomas. The XXXIII Edward Jackson Memorial Lecture." Am J Ophthalmol **83**: 299-323.
- Geisse, L. J., et al. (1985). "Iris melanomas." Am J Ophthalmol **99**: 638-648.
- Geissler, E. N., et al. (1988). "The dominant white spotting (w) locus of the mouse encodes the c-kit proto-oncogen." Cell **55**: 185-192.
- Girnita, L., et al. (2000). "Inhibition of N-linked glycosylation down-regulates insulin-like growth factor-1 receptor at the cell surface and kills Ewing's sarcoma cells: therapeutic implications." Anticancer Drug Des **15**: 67-72.
- Gonder, J. R., et al. (1982). "Ocular melanocytosis. A study to determine the prevalence rate of ocular melanocytosis." Ophthalmology **89**: 950-952.
- Gonder, J. R., et al. (1981). "Malignant melanoma of the choroid associated with oculodermal melanocytosis." Ophthalmology **88**: 372-376.
- Gragoudas, E. S., et al. (1980). "Proton beam irradiation. An alternative to enucleation for intraocular melanomas." Ophthalmology **87**: 571-581.
- Grant, M., et al. (1993). "Inhibition of IGF-1 and bFGF stimulated growth of human retinal endothelial cells by the somatostatin analog, octreotide: A potential treatment for ocular neovascularization." Regul Pept **48**: 267.
- Harrington, E. A., et al. (1994). "c-myc induced apoptosis in fibroblasts is inhibited by specific cytokines." Embo J **13**: 3286-3295.
- Hicklin, D. J., et al. (1999). "HLA class I downregulation in human cancers: T-cell immunotherapy revives an old story." Mol Med Today **5**: 178-186.
- Hirota, S., et al. (1998). "Gain-of-function mutations of c-kit in human gastrointestinal stromal tumors." Science **279**: 577-580.
- Holly, E. A., et al. (1990). "Uveal melanoma in relation to ultraviolet light exposure and host factors." Cancer Res(18): 5773-5777.
- Horsman, D. E., et al. (1993). "Cytogenetic analysis of uveal melanoma. Consistent occurrence of monosomy 3 and trisomy 8q." Cancer **71**: 811-819.
- Horsthemke, B., et al. (1992). "Loss of chromosome 3 alleles and multiplication of chromosome 8 alleles in uveal melanoma." Genes Chromosomes Cancer **4**: 217-221.
- Huizinga, J. (1995). "W/kit gene required for interstitial cells of Cajal and for intestinal pacemaker activity." Nature **373**: 347-349.

- Hurks, H. M., et al. (2000). "Expression of epidermal growth factor receptor: risk factor in uveal melanoma." Invest Ophthalmol Vis Sci **41**: 2023-2027.
- Irusta, P. M., et al. (1998). "A single amino-acid substitution in a WW-like domain of diverse members of the PDGF receptor subfamily of tyrosine kinases causes constitutive receptor activation." Embo J **17**: 6912-6923.
- Jager, M. J., et al. (1988). "Decreased expression of HLA class II antigens on human uveal melanoma cells after in vivo X-ray irradiation." Am J Ophthalmol **105**: 78-86.
- Jenkins, M. K., et al. (1987). "Antigen presentation by chemically modified splenocytes induces antigen-specific T-cell unresponsiveness in vitro and in vivo." J Exp Med **165**: 302-319.
- Jensen, O. A. (1970). "Malignant melanomas of the human uvea. Recent follow-up cases in Denmark, 1943-1952." Acta Ophthalmol **48**: 1113-1128.
- Jiang, L. Q., et al. (1993). "Subretinal space and vitreous cavity as immunologically privileged sites for retinal allografts." Invest Ophthalmol Vis Sci **34**: 3347-3354.
- Jiang, L. Q., et al. (1994). "Immunologic consequences of intraocular implantation of retinal pigment epithelial allografts." Exp Eye Res **58**: 719-728.
- Jiminez, P., et al. (1999). "Chromosome loss is the most frequent mechanism contributing to HLA haplotype loss in human tumors." Int J Cancer **83**: 91-97.
- Joensuu, H., et al. (2001). "Effect of the tyrosine inhibitor STI571 in a patient with a metastatic gastrointestinal stromal tumor." N Engl J Med **344**: 1052-1056.
- Kalebic, T., et al. (1994). "In vivo treatment with antibody against the IGF-1 receptor suppresses growth of human rhabdomyosarcoma and down regulates p34cdc2." Cancer Res **54**: 5531-5534.
- Kallioniemi, O. P., et al. (1994). "Optimizing comparative genomic hybridization for analysis of DNA sequence copy number changes in solid tumors." Genes Chromosomes Cancer **10**: 231-243.
- Kanter-Lewensohn, L., et al. (1998). "Expression of the insulin-like growth factor-1 receptor and its anti-apoptotic effect in malignant melanoma: a potential therapeutic target." Melanoma Res **8**: 389-397.
- Kath, R., et al. (1993). "Prognosis and treatment of disseminated uveal melanoma." Cancer **72**: 2219-2223.
- Koopman, L. A., et al. (2000). "Multiple genetic alterations cause frequent and heterogeneous human histocompatibility leukocyte antigen class I loss in cervical cancer." J Exp Med **191**: 961-965.

- Laemmli, U. K. (1970). "Cleavage of structural proteins during assembly of the head of bacteriophage T4." Nature **227**: 680-685.
- Lampson, L. A., et al. (1983). "Striking paucity of HLA-A, -B, -C and beta-2 microglobulin on human neuroblastoma cell lines." J Immunol **130**: 2471-2478.
- Larue, L., et al. (1992). "Spontaneous malignant transformation of melanocytes explanted from Wf/Wf mice with a Kit kinase-domain mutation." Proc Natl Acad Sci U S A **89**: 7816-7820.
- Lassam, N., et al. (1992). "Loss of c-kit expression in cultured melanoma cells." Oncogene **7**: 51-56.
- LeRoith, D., et al. (1992). "Insulin-like growth factors in health and disease." Ann Intern Med **116**: 854-862.
- Liao, N. S., et al. (1991). "MHC class I deficiency: susceptibility to natural killer (NK) cells and impaired NK activity." Science **253**: 199-202.
- Ma, D., et al. (1995). "Relationship between natural killer cell susceptibility and metastasis of human uveal melanoma cells in a murine model." Invest Ophthalmol Vis Sci **36**: 435-441.
- Ma, D., et al. (1998). "Role of epidermal growth factor receptor in the metastasis of intraocular melanomas." Invest Ophthalmol Vis Sci **39**: 1067-1075.
- Ma, Y., et al. (1999). "Inhibition of spontaneous receptor phosphorylation by residues in a putative alpha-helix in the KIT intracellular juxtamembrane region." J Biol Chem **274**: 13399-13402.
- Magnus, K. (1977). "Prognosis in malignant melanoma of the skin. Significance of stage of disease, anatomical site, sex, age and period of diagnosis." Cancer **40**: 389-397.
- Makitie, T., et al. (1999). "Microvascular loops and networks as prognostic indicators in choroidal and ciliary body melanomas." J Natl Cancer Inst **91**: 359-367.
- Marincola, F. M., et al. (2000). "Escape of human solid tumors from T cell recognition:molecular mechanisms and functional significance." Adv Immunol **74**: 181-185.
- Massague, J., et al. (1982). "The subunit structures of two distinct receptors for insulin-like growth factors I and II and their relationship to the insulin receptor." J Biol Chem **257**: 5038-5045.
- McLean, I. W., et al. (1983). "Modifications of Callender's classification of uveal melanoma at the Armed Forces Institute of Pathology." Am J Ophthalmol **96**: 502-509.

- McLean, M. J., et al. (1977). "Prognostic factors in small malignant melanomas of choroid and ciliary body." Arch Ophthalmol **95**: 48-58.
- McLean, M. N., et al. (1994). Tumors of the Uveal Tract, AFIP, DC.
- Metzelaar-Blok, J. A., et al. (1999). "Frequent loss of heterozygosity on chromosome 6p in uveal melanoma." Hum Immunol **60**: 962-969.
- Meyers, M. L., et al. (1998). Diagnosis and treatment of metastatic melanoma. Cutaneous Melanoma. M. C. Balch, A. N. Houghton, A. J. Sober and S. Soongs. St Louis, QMP: 325-372.
- Moore, R. F. (1930). "Choroidal sarcoma treated by the intraocular insertion of radio seeds." Br J Ophthalmol **14**: 145-156.
- Mouriaux, F., et al. (2001). "Implication of stem cell factor in the proliferation of choroidal melanocytes." Exp Eye Res **73**: 151-157.
- Myers, M. G. J., et al. (1993). "IRS-1 is a common element in insulin and insulin-like growth factor-I signaling to the phosphatidylinositol 3'-kinase." Endocrinology **132**: 1421-1430.
- Nagata, H., et al. (1995). "Identification of a point mutation in the catalytic domain of the proto oncogene c-kit in peripheral blood mononuclear cells of patients who have mastocytosis with an associated hematologic disorder." Proc Natl Acad Sci U S A **92**: 10560-10564.
- Nakata, Y., et al. (1995). "C-kit point-mutation of extracellular domain in patients with myeloproliferative disorders." Br J Haematol **91**: 661-663.
- Natali, P. G., et al. (1992). "Progression of human cutaneous melanoma is associated with loss of expression of c-kit proto-oncogene receptor." Int J Cancer **52**: 197-201.
- Naumann, G. O., et al. (1966). "Histogenesis of malignant melanomas of the uvea. I. Histopathologic characteristics of nevi of the choroid and ciliary body." Arch Ophthalmol **76**: 784-796.
- Naus, N. C., et al. (2002). "Detection of Genetic Prognostic Markers in Uveal Melanoma Biopsies Using Fluorescence in Situ Hybridization." Clin Cancer Res **8**: 534-539.
- Niederhorn, J. Y. (1990). "Immune privilege and immune regulation in the eye." Adv Immunol **48**: 191-226.
- Oosterhuis, J. A., et al. (1995). "Transpupillary thermotherapy in choroidal melanomas." Arch Ophthalmol **113**: 315-321.

- Oosterhuis, J. A., et al. (1998). "Transpupillary thermotherapy: results in 50 patients with choroidal melanoma." Arch Ophthalmol **116**: 157-162.
- Osterlind, A. (1987). "Trends in incidence of ocular malignant melanoma in Denmark 1943-1982." Int J Cancer **40**: 161-164.
- Pach, J. M., et al. (1986). "Metastasis from untreated uveal melanomas." Arch Ophthalmol **104**: 1624-1625.
- Packer, S. (1987). "Iodine-125 radiation of posterior uveal melanoma." Ophthalmology **94**(12): 1621-6.
- Packer, S., et al. (1980). "Irradiation of choroidal melanoma with iodine 125 ophthalmic plaque." Arch Ophthalmol **98**: 1453-1457.
- Pardee, A. B. (1989). "G1 events and regulation of cell proliferation." Science **246**: 603-608.
- Patel, K. A., et al. (2002). "Prediction of prognosis in patients with uveal melanoma using fluorescence in situ hybridization." Br J Ophthalmol **85**: 1440-1444.
- Pawson, T. (1995). "Protein modules and signalling networks." Nature **373**: 573-580.
- Pellegrino, M. A., et al. (1982). Unorthodox expression of Ia-like antigens on human tumor cells of nonlymphoid origin: immunological properties, structural profile and clinical relevance. Immunologic Analysis. Recent Progress in Diagnostic Laboratory Immunology. New York, Mason: 159-173.
- Peruzzi, F., et al. (1999). "Multiple signaling pathways of the insulin-like growth factor-1 receptor in protection from apoptosis." Molecular and cellular biology **19**: 7203-7215.
- Petley, T., et al. (1999). "Variation among cell types in the signaling pathways by which IGF-I stimulates specific cellular responses." Horm Metab Res **31**: 70-76.
- Peyman, G. A., et al. (1984). "Ten years experience with eye wall resection for uveal malignant melanomas." Ophthalmology **91**: 1720-1725.
- Prager, D., et al. (1994). "Dominant negative inhibition of tumorigenesis in vivo by human insulin-like growth factor-1 receptor mutant." Proc Natl Acad Sci U S A **91**: 2181-2185.
- Prescher, G., et al. (1995). "Cytogenetics of twelve cases of uveal melanoma and patterns of nonrandom anomalies and isochromosome formation." Cancer Genet Cytogenet **80**: 40-46.
- Prescher, G., et al. (1996). "Prognostic implications of monosomy 3 in uveal melanoma." Lancet **347**: 1222-1225.

- Raivio, I. (1977). "Uveal melanoma in Finland. An epidemiological, clinical, histological and prognostic study." Acta Ophthalmol Suppl **133**: 1-64.
- Rajpal, S., et al. (1983). "Survival in metastatic ocular melanoma." Cancer **52**: 334-336.
- Rees, R. C., et al. (1999). "Selective MHC expression in tumours modulates adaptive and innate antitumour responses." Cancer Immunol . Immunother. **48**: 374-381.
- Ren, S. G., et al. (1992). "Somatostatin analog induces insulin-like growth factor binding protein-1 (IGFBP-1) expression in human hepatoma cells." Endocrinology **131**: 2479-2481.
- Repp, A. C., et al. (2000). "Human uveal melanoma cells produce macrophage migration-inhibitory factor to prevent lysis by NK cells." J Immunol **165**: 710-715.
- Resnicoff, M., et al. (1995). "The insulin-like growth factor-1 receptor protects tumor cells from apoptosis in vivo." Cancer Res **55**: 2463-2469.
- Resnicoff, M., et al. (1994). "Growth inhibition of human melanoma cells in nude mice by antisense strategies to the type 1 insulin-like growth factor receptor." Cancer Res **54**: 4848-4850.
- Resnicoff, M., et al. (1994). "Rat glioblastoma cells expressing an antisense RNA to the insulin-like growth factor-1 receptor are nontumorigenic and induce regression of wild-type tumors." Cancer Res **54**: 2218-2222.
- Reubi, J. C., et al. (1995). "Multiple actions of somatostatin in neoplastic disease." Trends Pharmacol Sci **16**: 110.
- Roehm, N. W., et al. (1991). "An improved colorimetric assay for cell proliferation and viability utilizing the tetrazolium salt XTT." J Immunol Assay **142**: 257-265.
- Rowley, D. (1973). "A new consistent chromosomal abnormality in chronic myelogenous leukemia identified by quinacrine fluorescence and Giemsa staining." Nature **243**: 290-293.
- Rubin, R., et al. (1995). "Insulin-like growth factor-I receptor. Its role in cell proliferation, apoptosis and tumorigenicity." Lab Invest **73**: 311-331.
- Rummelt, V., et al. (1995). "Relation between the microcirculation architecture and the aggressive behavior of ciliary body melanomas." Ophthalmology **102**: 844-851.
- Sahel, J. A., et al. (1997). Intraocular melanomas. Cancer: Principles and Practice of Oncology. V. T. j. DeVita, S. Hellman and S. A. Rosenberg. Philadelphia, Lippincott: 1995-2011.
- Sakamoto, T., et al. (1996). "Histologic findings and prognosis of uveal malignant melanoma in japanese patients." Am J Ophthalmol **121**: 276-283.

- Sara, V. R., et al. (1990). "Insulin-like growth factors and their binding proteins." *Physiol Rev* **70**: 591-614.
- Scholes, A. G., et al. (2001). "Overexpression of epidermal growth factor receptor restricted to macrophages in uveal melanoma." *Arch Ophthalmol* **119**: 373-377.
- Schubert (1925). "Operation eines leucosarkomas der choroidea mit Erhaltung des Auges." *Wien Klin Wochenschr* **38**: 677-678.
- Schwartz, L. H., et al. (1997). "Lack of correlation between the location of choroidal melanoma and ultraviolet-radiation dose distribution." *Radiat Res* **147**: 451-456.
- Seddon, J. M., et al. (1983). "A prognostic factor study of disease-free interval and survival following enucleation for uveal melanoma." *Arch Ophthalmol* **101**: 1894-1899.
- Seddon, J. M., et al. (1987). "Death from uveal melanoma. Number of epithelioid cells and inverse SD of nucleolar area as prognostic factors." *Arch Ophthalmol* **105**: 801-806.
- Seliger, B., et al. (2000). "Antigen-processing machinery breakdown and tumor growth." *Immunol Today* **21**: 455-464.
- Sell, C., et al. (1995). "Insulin-like growth factor-1 (IGF-1) and the IGF-1 receptor prevent etoposide-induced apoptosis." *Cancer Res* **55**: 303-306.
- Seregard, S., et al. (2001). "Transpupillary thermotherapy as an adjunct to ruthenium plaque radiotherapy for choroidal melanoma." *Acta Ophthalmol Scand* **79**(1): 19-22.
- Seregard, S., et al. (1996). "PC-10 as a predictor of prognosis after antigen retrieval in posterior uveal melanoma." *Invest Ophthalmol Vis Sci* **37**: 1451-1458.
- Seregard, S., et al. (1998). "Prognostic accuracy of the mean of the largest nucleoli, vascular patterns, and PC-10 in posterior uveal melanoma." *Ophthalmology* **105**: 485-491.
- Shapiro, D. N., et al. (1994). "Antisense-mediated reduction in insulin-like growth factor-1 receptor suppresses the malignant phenotype of human alveolar rhabdomyosarcoma." *J Clin Invest* **94**: 1235-1242.
- Shields, C. L., et al. (2002). "Combined plaque radiotherapy and transpupillary thermotherapy for choroidal melanoma: tumor control and treatment complications in 270 consecutive patients." *Arch Ophthalmol* **120**(933-940).
- Shields, C. L., et al. (2002). "Clinical features of small choroidal melanoma." *Curr Opin Ophthalmol* **13**: 135-141.

- Shields, C. L., et al. (1998). "Transpupillary thermotherapy for choroidal melanoma: tumor control and visual results in 100 consecutive cases." Ophthalmology **105**: 581-590.
- Shields, C. L., et al. (2001). "Iris melanoma: risk factors for metastasis in 169 consecutive patients." Ophthalmology **108**: 172-178.
- Shields, J. A., et al. (1980). "The differential diagnosis of posterior uveal melanoma." Ophthalmology **87**: 518-522.
- Shields, J. A., et al. (1992). Introduction to melanocytic tumors of the uvea. Intraocular Tumors. A Text and Atlas. J. A. Shields and C. L. Shields. Philadelphia, WB Saunders: 45-59.
- Shields, J. A., et al. (1991). "Management of posterior uveal melanoma." Surv Ophthalmol **36**: 161-195.
- Sisley, K., et al. (2000). "Association of specific chromosome alterations with tumour phenotype in posterior uveal melanoma." Br J Cancer **82**: 330-338.
- Sisley, K., et al. (1997). "Abnormalities of chromosomes 3 and 8 in posterior uveal melanoma correlate with prognosis." Genes Chromosomes Cancer **19**: 22-28.
- Spritz, R. A., et al. (1993). "Novel mutations of the KIT (mast/stem cell growth factor receptor) proto-oncogene in human piebaldism." J Invest Dermatol **101**: 22-25.
- Stallard, H. B. (1966). "Radiotherapy for malignant melanoma of the choroid." Br J Ophthalmol **50**: 147-155.
- Stam, N. J., et al. (1986). "Monoclonal antibodies raised against denaturated HLA-B locus heavy chains permit biochemical characterization of certain HLA-C locus products." J Immunol **137**: 2299-2306.
- Stehlin, J. S., et al. (1967). "Disseminated melanoma: biological behavior and treatment." Arch Surg **94**: 945-951.
- Storkus, W. J., et al. (1987). "NK susceptibility varies inversely with target cell class I HLA antigen expression." J. Immunol **138**: 1657-1659.
- Streilein, J. W. (1995). "Unraveling immune privilege." Science **270**: 1158-1159.
- Strickland, D., et al. (1981). "Melanomas of eye: stability of rates." Am J Epidemiol **113**: 700-702.
- Tannock, I. F., et al. (1992). The basic science of oncology. New York, McGraw-Hill.
- Temponi, M., et al. (1993). "Characterization of anti-HLA class II monoclonal antibody LGII-612.14 reacting with formalin-fixed tissues." J Immunol Methods **161**: 239-256.

- Thomson, F., et al. (1995). "Cytogenetics of 158 patients with regional or disseminated melanoma. Subset analysis of near-diploid and simple karyotypes." Cancer Genet Cytogenet **83**: 93-104.
- Tian, Q., et al. (1999). "Activating c-kit gene mutations in human germ cell tumors." Am J Pathol **154**: 1643-1647.
- Ullrich, A., et al. (1986). "Insulin-like growth factor-1 receptor primary structure: comparison with insulin receptor suggests structural determinants that define functional specificity." Embo J **5**(1): 2503-2512.
- Wagoner, M. D., et al. (1982). "The incidence of metastases from untreated ciliary body and choroidal melanoma." Arch Ophthalmol **100**: 939-940.
- van den Elsen, P. J., et al. (1998). "Regulation of MHC class I and II gene transcription: differences and similarities." Immunogenetics **48**: 208-221.
- van den Oord, J. J., et al. (1994). "Bcl-2 expression in human melanocytes and melanocytic tumors." Am J Pathol **145**: 294-300.
- Wang, Z., et al. (1996). "Molecular and functional phenotypes of melanoma cells with abnormalities in HLA class I antigen expression." Tissue Antigens **47**: 382-390.
- White, V. A., et al. (1998). "Correlation of cytogenetic abnormalities with the outcome of patients with uveal melanoma." Cancer **83**: 354-359.
- Williams, D. E. (1990). "Identification of a ligand for the c-KIT proto-oncogene." Cell **63**: 167-174.
- Xie, Y., et al. (1999). "Expression of insulin-like growth factor-1 receptor in synovial sarcoma: association with an aggressive phenotype." Cancer Res **59**: 3588-3591.
- Yanhoff, M., et al. (1967). "Histogenesis of malignant melanomas of the uvea . II. Relationship of uveal nevi to malignant melanomas." Cancer **20**: 493-507.
- Yarden, Y. (1987). "Human proto-oncogene c-KIT: a new cell surface receptor tyrosine kinase for an unidentified ligand." Embo J **6**: 3341-3351.
- Yarden, Y., et al. (1988). "Growth factor receptor tyrosine kinases." Annu Rev Biochem **57**: 443-478.
- Yoshida, H., et al. (1993). "The role of c-kit proto-oncogene during development in mouse. In vivo approach by the in utero microinjection of anti-c-kit antibody." Dev Growth Differ **35**: 209-220.
- Yumi, K., et al. (1997). "Direct effects of somatostatin analog octreotid on insulin-like growth factor-1 in the arterial wall." Lab Invest **76**: 329.

- Zakut, R., et al. (1993). "KIT ligand (mast cell growth factor) inhibits the growth of KIT expressing melanoma cell lines." Oncogene **8**: 2221-2239.
- Zimmerman, L. E., et al. (1983). "The pathogenesis of metastasis from uveal melanomas." Ophthalmic Forum **1**: 28-29.
- Zimmerman, L. E., et al. (1978). "Does enucleation of the eye containing a malignant melanoma prevent or accelerate the dissemination of tumour cells." Br J Ophthalmol **62**: 420-425.
- Zirm (1911). "Uber endobulbare operationen." Arch Augenheilkd **69**: 233-251.
- Zsebo, K. M., et al. (1990). "Stem cell factor is encoded at the Sl locus of the mouse and its ligand for the c-kit tyrosine kinase receptor." Cell **63**: 213-224.